Orthopod®
Enabling your orthopaedic practice

A Patient's Guide to

Pes Anserine Bursitis

©MMG 2003

Concord Orthopaedics
264 Pleasant Street
Concord, NH 03301
Phone: 6032243368 Fax: 6032287268
marketing.COPA@concordortho.com

CONCORD ORTHOPAEDICS

Compliments of: **Concord Orthopaedics**

Concord Orthopaedics

Concord Orthopaedics
264 Pleasant Street
Concord, NH 03301
Phone: 6032243368 Fax: 6032287268
marketing.COPA@concordortho.com
https://concordortho.com

All materials within these pages are the sole property of Mosaic Medical Group, LLC and are used herein by permission. eOrthopod is a registered trademark of Mosaic Medical Group, LLC.

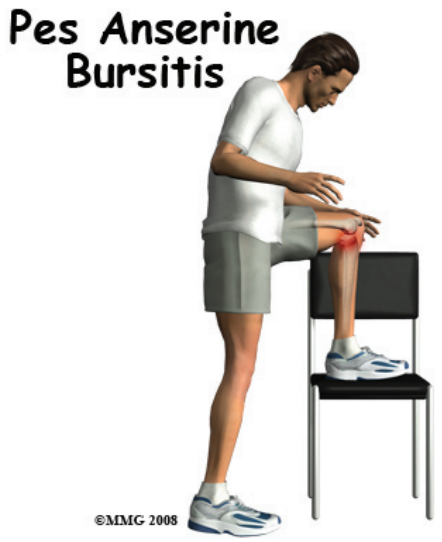

Introduction

Bursitis of the knee occurs when constant friction on the *bursa* causes inflammation. The bursa is a small sac that cushions the bone from tendons that rub over the bone. Bursae can also protect other tendons as tissues glide over one another. Bursae can become inflamed and irritated causing pain and tenderness.

This guide will help you understand

- **what part of the knee is affected**
- **what causes this condition**
- **how the doctors diagnosis this condition**
- **what treatment options are available**

Anatomy

What parts of the knee are affected?

The pes anserine bursa is the main area affected by this condition. The pes anserine bursa is a small lubricating sac between the *tibia* (shinbone) and the hamstring muscle. The hamstring muscle is located along the back of the thigh.

There are three tendons of the hamstring: the *semitendinosus*, *semimembranosus*, and the *biceps femoris*. The semitendinosus wraps

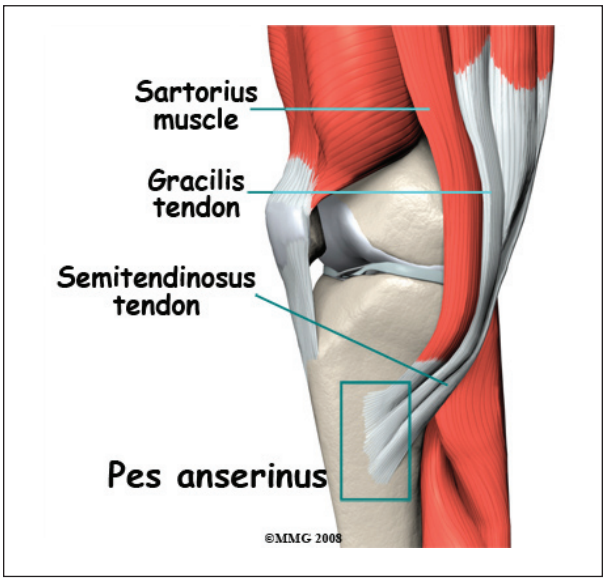

around from the back of the leg to the front. It inserts into the *medial* surface of the tibia and deep connective tissue of the lower leg. Medial refers to the inside of the knee or the side closest to the other knee.

Just above the insertion of the semitendinosus tendon is the *gracilis* tendon. The gracilis muscle *adducts* or moves the leg toward the body. The semitendinosus tendon is also just behind the attachment of the *sartorius* muscle. The sartorius muscle bends and externally rotates the hip. Together, these three tendons splay out on the tibia and look like a goose-foot. This area is called the *pes anserine* or *pes anserinus*.

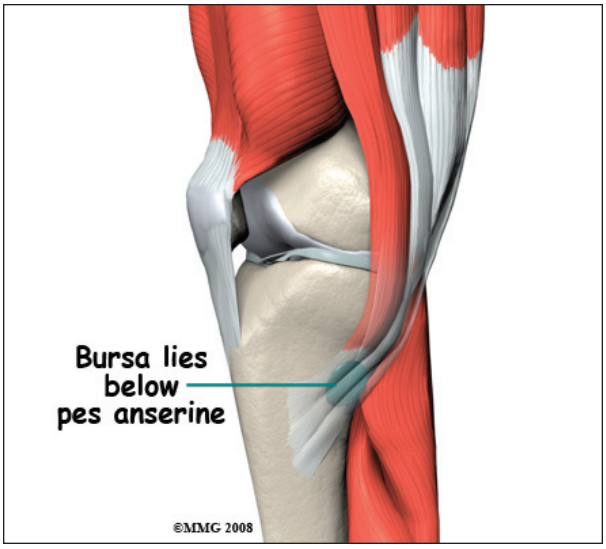

The pes anserine bursa provides a buffer or lubricant for motion that occurs between these three tendons and the *medial collateral ligament* (MCL). The MCL is underneath the semitendinosus tendon.

Causes

What causes this condition?

Overuse of the hamstrings, especially in athletes with tight hamstrings is a common cause of goosefoot. Runners are affected most often. Improper training, sudden increases in distance run, and running up hills can contribute to this condition.

It can also be caused by trauma such as a direct blow to this part of the knee. A contusion to this area results in an increased release of synovial fluid in the lining of the bursa. The bursa then becomes inflamed and tender or painful.

Anyone with osteoarthritis of the knee is also at increased risk for this condition. And alignment of the lower extremity can be a risk factor for some individuals. A turned out position of the knee or tibia, *genu valgum* (knock knees), or a flatfoot position can lead to pes anserine bursitis.

Symptoms

What does this condition feel like?

The patient often points to the pes anserine as the area of pain or tenderness. The pes anserine is located about two to three inches below the joint on the inside of the knee. This is referred to as the *anterior* knee or *proximedia* tibia. Proximedia is short for proximal and medial. This term refers to the front inside edge of the tibia.

Some patients also have pain in the center of the tibia. This occurs when other structures are also damaged such as the *meniscus* (cartilage). The pain is made worse by exercise, climbing stairs, or activities that cause resistance to any of these tendons.

Diagnosis

How do doctors diagnose this condition?

A history and clinical exam will help the physician differentiate pes anserine bursitis from other causes of anterior knee pain, such as patellofemoral syndrome or arthritis. An X-ray is needed to rule out a stress fracture or arthritis. An MRI may be needed to look for damage to other areas of the medial compartment of the knee. Fluid from the bursa may be removed and tested if infection is suspected.

The examiner will also assess hamstring tightness. This is done in the *supine* position (lying on your back). Your hip is *flexed* (bent) to 90 degrees. The knee is straightened as far as possible. The amount of knee flexion is an indication of how tight the hamstrings are. If you can straighten your knee all the way in this position, then you do not have tight hamstrings.

Treatment

What treatment options are available?

Nonsurgical Treatment

The goal of treatment for overuse injuries such as pes anserine bursitis is to reduce the strain on the injured tissues. Stopping the activity that brings on or aggravates the symptoms is the first step toward pain reduction.

Bedrest is not required but it may be necessary to modify some of your activities. This will give time for the bursa to quiet down and for the pain to subside. Patients are advised to avoid stairs, climbing, or other irritating activities. This type of approach is called *relative rest*.

Ice and antiinflammatory medications can be used in the early, inflammatory phase. The ice is applied three or four times each day for 20 minutes at a time. Ice cubes wrapped in a thin layer of toweling or a bag of frozen vegetables applied to the area works well.

Athletes are often instructed by their physical therapist or athletic trainer to perform an ice massage. A cup of water is frozen in a Styrofoam container. The top edge of the container is torn away leaving a one-inch surface of ice that can be rubbed around the area. The Styrofoam protects the hand of the person holding the cup while applying the ice massage. The pes anserine area is massaged with the ice for 10 minutes or until the skin is numb. Caution is advised to avoid frostbite.

Over-the-counter *nonsteroidal antiinflammatory drugs* (NSAIDs) such as Ibuprofen may be advised. In some cases, the physician will prescribe stronger NSAIDs. Your physical therapist can also use a process called *iontophoresis*. Using an electric charge, an antiinflammatory drug can be pushed through the skin to the inflamed area. This method is called *transdermal drug delivery*. Iontophoresis puts a higher concentration of the drug directly in the area compared to taking medications by mouth. This process does not deliver as much drug as a local injection.

Improving flexibility is a key part of the prevention and treatment of this condition. Hamstring stretching is performed at least twice a day for a minimum of 30 seconds each time. Holding the stretch for a full minute has been proven even more effective. Some patients must perform this stretch more often – even once an hour if necessary.

Do not bounce during the stretch. Hold the position at a point of feeling the stretch but not so far that it is painful or uncomfortable. Deep breathing can help ease the discomfort. Try to stretch a little more as you breathe out.

Quadriceps strengthening is also important. This is especially true if there are other areas of the knee affected. The quadriceps muscle along the front of the thigh extends the knee and helps balance the pull of the hamstrings.

A special type of exercise program called *closed kinetic chain* (CKC) is performed for six to eight weeks to assist with quadriceps strengthening. The CKC may include single-knee dips, squats and leg presses. Resisted leg-pulls using elastic tubing are also included. The exercise program is prescribed by a physical therapist and gradually progressed during the eight-week session.

If these measures are not enough, your physician may inject the bursa with a solution of lidocaine (an anesthetic or numbing agent)

combined with a steroid (an antiinflammatory). The steroid injection can be diagnostic as well. If the symptoms are improved, it is assumed the problem was coming from the pes anserine bursa.

Surgery

Surgery is rarely needed for pes anserine bursitis. The bursa may be removed if chronic infection cannot be cleared up with antibiotics.

Rehabilitation

What should I expect after treatment?

Nonsurgical Rehabilitation

Pes anserine bursitis is considered a *self-limiting* condition. This means it usually responds well to treatment and will resolve without further intervention. Athletes may have to continue a program of hamstring stretching and CKC quadriceps strengthening on a regular basis.

Athletes may return to sports or play when the symptoms are gone and are no longer aggravated by certain activities. Protective gear for the knee may be needed for those individuals who participate in contact sports. During the rehab process, activity level and duration are gradually increased. If the symptoms don't come back, the athlete can continue to progress to full participation in all activities.

After Surgery

If the bursa is removed, you follow the same steps of rehab and recovery outlined under Nonsurgical Treatment.

Notes