

A Patient's Guide to **Shoulder Anatomy**



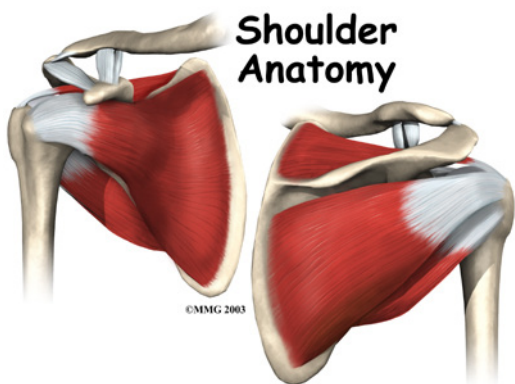
©MMG 2003



Summit Orthopedics



Summit Orthopedics
2321 Coronado
Idaho Falls, ID 83404
Phone: 208-227-1100
jdenny@summitortho.net
<http://www.summitortho.net/>



Introduction

The shoulder is an elegant piece of machinery. It has the greatest range of motion of any joint in the body. However, this large range of motion can lead to joint problems.

Understanding how the different layers of the shoulder are built and connected can help you understand how the shoulder works, how it can be injured, and how challenging recovery can be when the shoulder is injured. The deepest layer of the shoulder includes the bones and the joints. The next layer is made up of the ligaments of the joint capsule. The tendons and the muscles come next.

This document will help you understand:

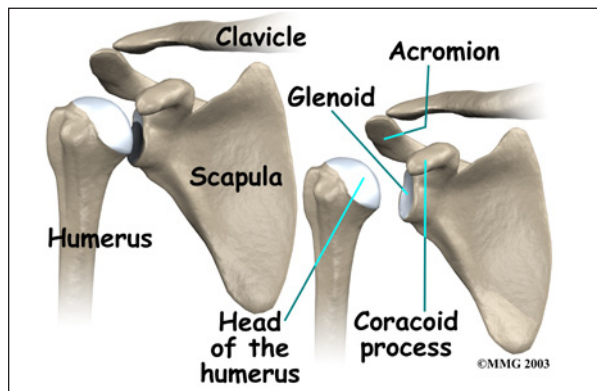
- what parts make up the shoulder
- how these parts work together

Important Structures

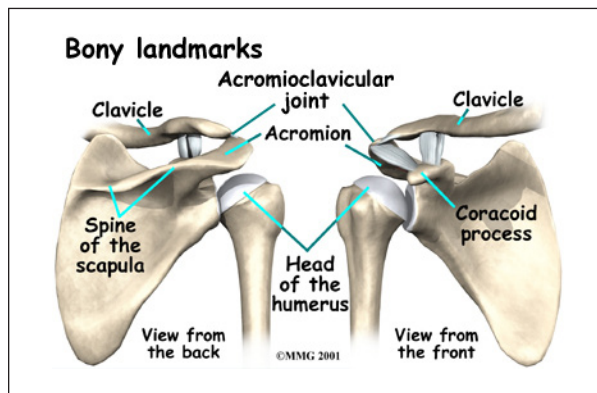
The important structures of the shoulder can be divided into several categories. These include

- bones and joints
- ligaments and tendons
- muscles
- nerves
- blood vessels
- bursae

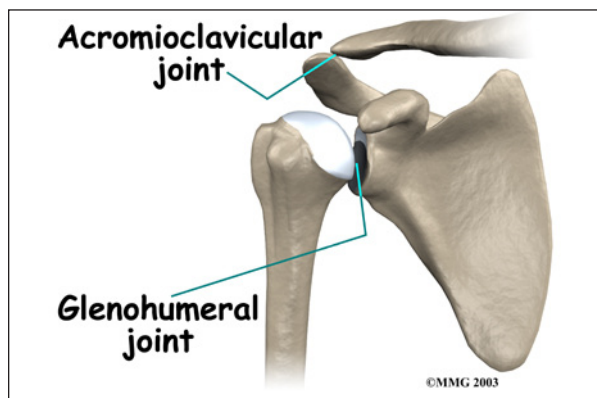
Bones and Joints



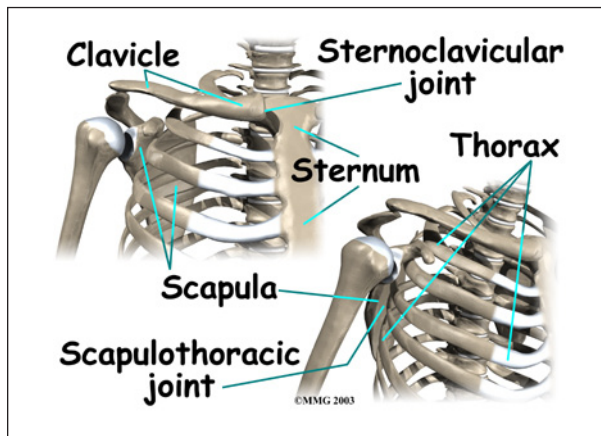
The **bones of the shoulder** are the *humerus* (the upper arm bone), the *scapula* (the shoulder blade), and the *clavicle* (the collar bone). The roof of the shoulder is formed by a part of the scapula called the *acromion*.



There are actually four joints that make up the shoulder. The main shoulder joint, called the *glenohumeral joint*, is formed where the ball of the humerus fits into a shallow socket on the scapula. This shallow socket is called the *glenoid*.



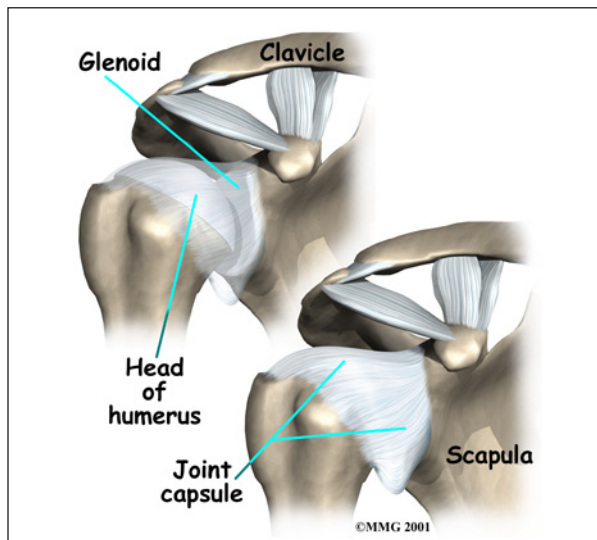
The **acromioclavicular (AC) joint** is where the clavicle meets the acromion. The **sternoclavicular (SC) joint** supports the connection of the arms and shoulders to the main skeleton on the front of the chest.



A *false joint* is formed where the shoulder blade glides against the *thorax* (the rib cage). This joint, called the **scapulothoracic joint**, is important because it requires that the muscles surrounding the shoulder blade work together to keep the socket lined up during shoulder movements.

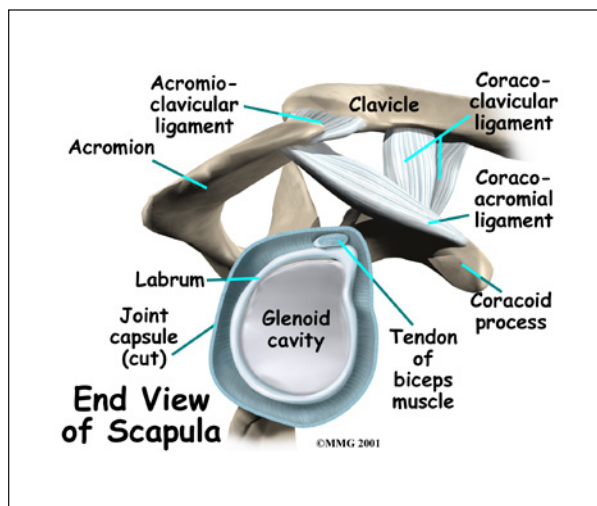
Articular cartilage is the material that covers the ends of the bones of any joint. Articular cartilage is about one-quarter of an inch thick in most large, weight-bearing joints. It is a bit thinner in joints such as the shoulder, which don't normally support weight. Articular cartilage is white and shiny and has a rubbery consistency. It is slippery, which allows the joint surfaces to slide against one another without causing any damage. The function of articular cartilage is to absorb shock and provide an extremely smooth surface to make motion easier. We have articular cartilage essentially everywhere that two bony surfaces move against one another, or *articulate*. In the shoulder, articular cartilage covers the end of the humerus and socket area of the glenoid on the scapula.

Ligaments and Tendons



There are several important *ligaments* in the shoulder. Ligaments are soft tissue structures that connect bones to bones. A *joint capsule* is a watertight sac that surrounds a joint. In the shoulder, the joint capsule is formed by a group of ligaments that connect the humerus to the glenoid. These ligaments are the main source of stability for the shoulder. They help hold the shoulder in place and keep it from dislocating.

Ligaments attach the clavicle to the acromion in the AC joint. Two ligaments connect the clavicle to the scapula by attaching to the *coracoid process*, a bony knob that sticks out of the scapula in the front of the shoulder.



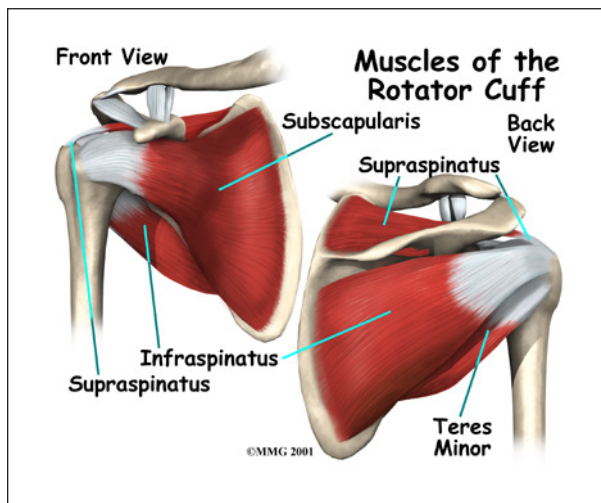
structure inside the shoulder called the *labrum*. The labrum is attached almost completely around the edge of the glenoid. When viewed in cross section, the labrum is wedge-shaped. The shape and the way the labrum is attached create a deeper cup for the glenoid socket. This is important because the glenoid socket is so flat and shallow that the ball of the humerus does not fit tightly. The labrum creates a deeper cup for the ball of the humerus to fit into.

The labrum is also where the *biceps tendon* attaches to the glenoid. *Tendons* are much like ligaments, except that tendons attach muscles to bones. Muscles move the bones by pulling on the tendons. The biceps tendon runs from the biceps muscle, across the front of the shoulder, to the glenoid. At the very top of the glenoid, the biceps tendon attaches to the bone and actually becomes part of the labrum. This connection can be a source of problems when the biceps tendon is damaged and pulls away from its attachment to the glenoid.

The tendons of the *rotator cuff* are the next layer in the shoulder joint. Four rotator cuff tendons connect the deepest layer of muscles to the humerus.

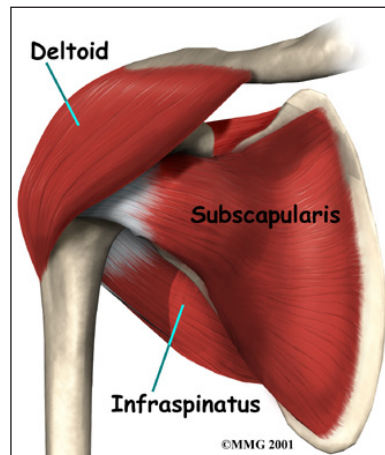
Muscles

The **rotator cuff** tendons attach to the deep rotator cuff muscles. This group of muscles lies just outside the shoulder joint. These



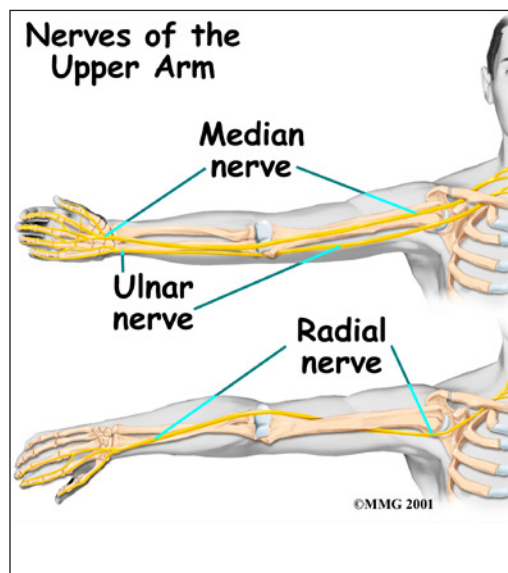
muscles help raise the arm from the side and rotate the shoulder in the many directions. They are involved in many day-to-day activities. The rotator cuff muscles and tendons also help keep the shoulder joint stable by holding the humeral head in the glenoid socket.

The large **deltoid** muscle is the outer layer of shoulder muscle. The deltoid is the largest, strongest muscle of the shoulder. The deltoid muscle takes over lifting the arm once the arm is away from the side.



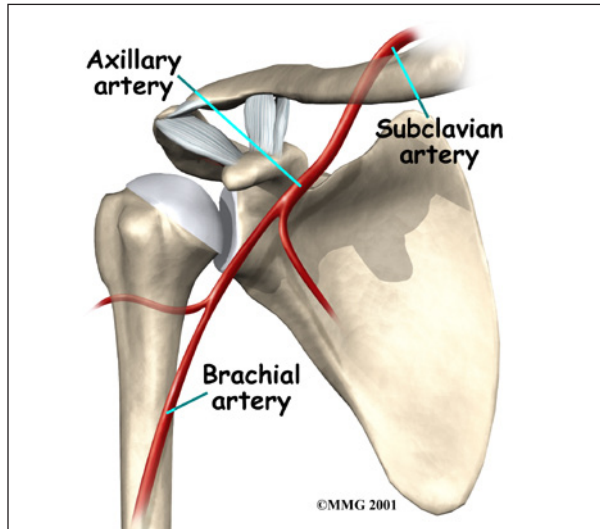
Nerves

The main nerves that travel into the arm run through the axilla under the shoulder. Three main nerves begin together at the shoulder: the *radial nerve*, the *ulnar nerve*, and the *median nerve*. These nerves carry the signals from the brain to the muscles that move the arm. The nerves also carry signals back to the brain about sensations such as touch, pain, and temperature. There is also an important



nerve that travels around the back of the shoulder joint to supply sensation to a small area of skin on the outside of the shoulder and motor signals to the deltoid muscle. This nerve is called the *axillary nerve*.

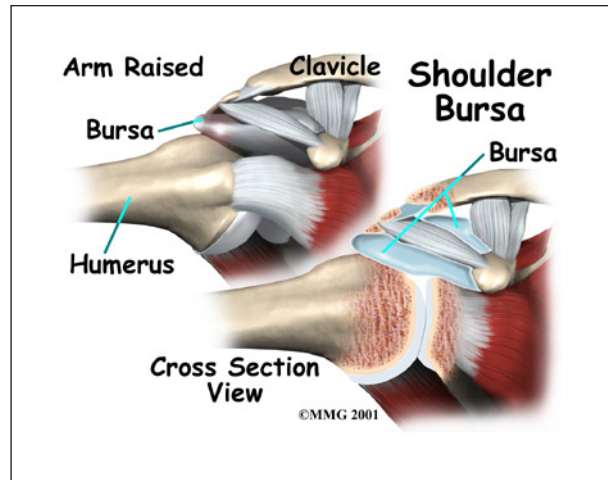
Blood Vessels



Traveling along with the nerves are the large vessels that supply the arm with blood. The large *axillary artery* travels through the axilla. If you place your hand in your armpit, you may be able to feel the pulsing of this large artery. The axillary artery has many smaller branches that supply blood to different parts of the shoulder. The shoulder has a very rich blood supply.

Bursae

Sandwiched between the rotator cuff muscles and the outer layer of large bulky shoulder muscles are structures known as *bursae*. Bursae are everywhere in the body. They are found wherever two body parts move against one another and there is no joint to reduce the friction. A single bursa is simply a sac between two moving surfaces that contains a small amount of lubricating fluid.



Think of a bursa like this: If you press your hands together and slide them against one another, you produce some friction. In fact, when your hands are cold you may rub them together briskly to create heat from the friction. Now imagine that you hold in your hands a small plastic sack that contains a few drops of salad oil. This sack would let your hands glide freely against each other without a lot of friction.

Summary

As you can see, the shoulder is extremely complex, with a design that provides maximum mobility and range of motion. Besides big lifting jobs, the shoulder joint is also responsible for getting the hand in the right position for any function. When you realize all the different ways and positions we use our hands every day, it is easy to understand how hard daily life can be when the shoulder isn't working well.

Notes