

## *A Patient's Guide to* **Kienbock's Disease**



©MMG 2003



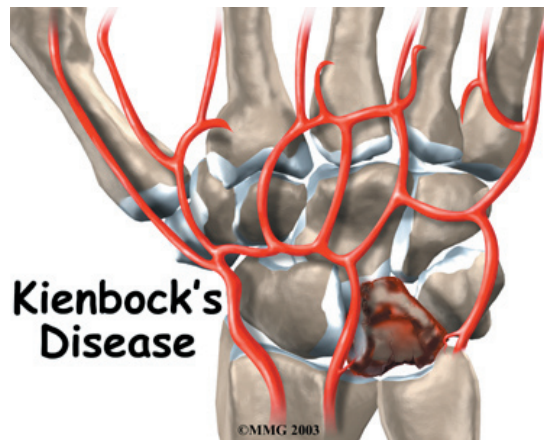
## Summit Orthopedics



Summit Orthopedics  
2321 Coronado  
Idaho Falls, ID 83404  
Phone: 208-227-1100  
jdenny@summitortho.net  
<http://www.summitortho.net/>

All materials within these pages are the sole property of Mosaic Medical Group, LLC and are used herein by permission. eOrthopod is a registered trademark of Mosaic Medical Group, LLC.

---



## Introduction

*Kienbock's disease* is a condition in which one of the small bones of the wrist loses its blood supply and dies, causing pain and stiffness with wrist motion. In the late stages of the disease, the bone collapses, shifting the position of other bones in the wrist. This shifting eventually leads to degenerative changes and osteoarthritis in the joint. While the exact cause of this uncommon disease isn't known, a number of treatment options are available.

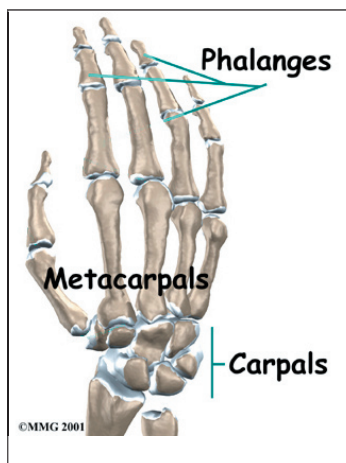
**This guide will help you understand**

- how Kienbock's disease develops
- how doctors diagnose the condition
- what treatment options are available

## Anatomy

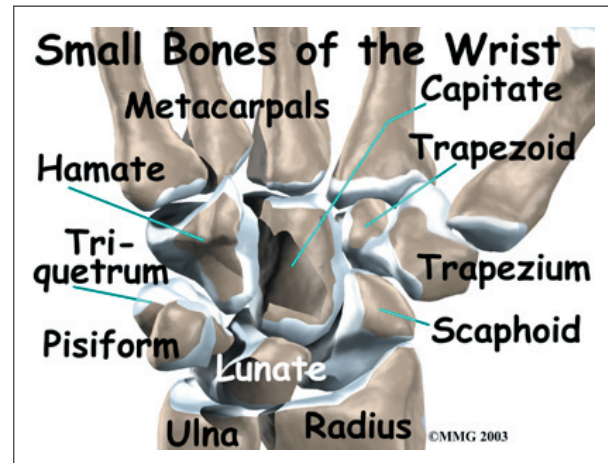
How does the wrist joint work?

The anatomy of the wrist joint is extremely complex, probably the most complex of all the joints in the body. The wrist is actually

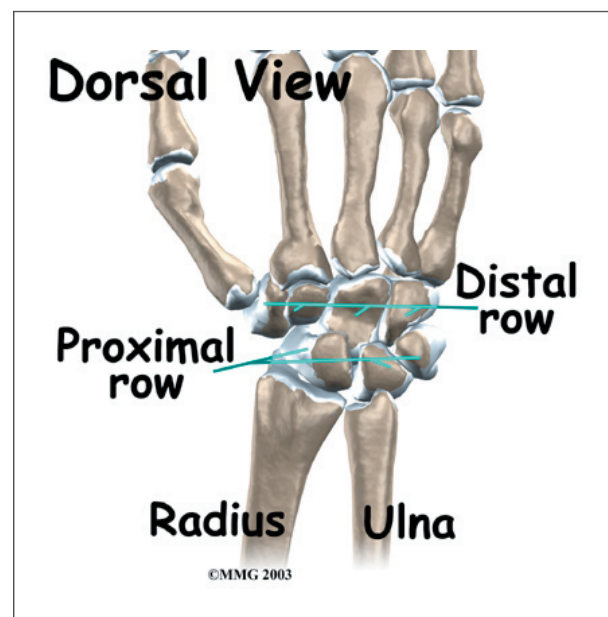


a collection of many joints and bones. These joints and bones let us use our hands in lots of different ways. The wrist must be extremely mobile to give our hands a full range of motion. At the same time, the wrist must provide the strength for heavy gripping.

The wrist is made of eight separate small bones, called the *carpal bones*. The *lunate* is one of these bones. It is the bone that is affected in patients with Kienbock's disease.



The carpal bones connect the **two bones of the forearm**, the *radius* and the *ulna*, to the bones of the hand. The *metacarpal* bones are the long bones that lie underneath the palm. The metacarpals attach to the *phalanges*, which are the bones in the fingers and thumb.



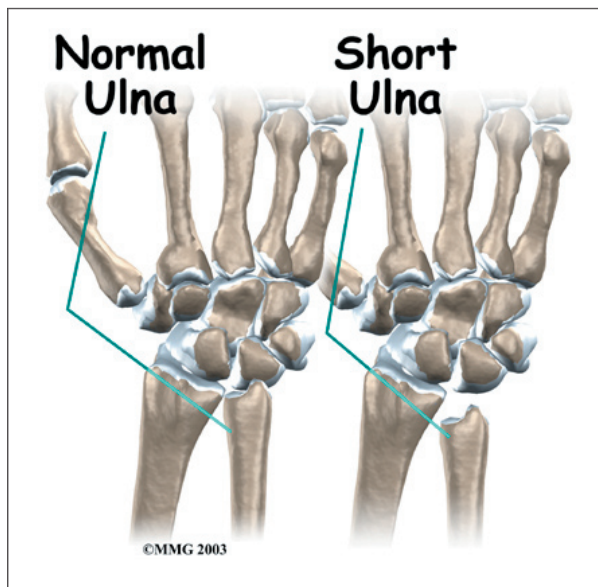
## Causes

Why do I have this condition?

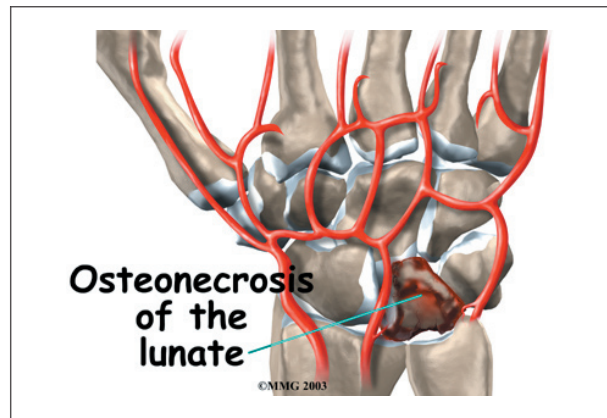
Doctors have not determined exactly what causes Kienbock's disease. A number of factors seem to be involved. Usually the patient has injured the wrist. The injury may be a single incident, such as a sprain, or a repetitive trauma. But the injury alone does not seem to cause the disease.

The way that blood vessels supply the lunate is thought to play a role in Kienbock's disease. Some bones in the body simply have fewer blood vessels that bring in blood. The lunate is one of those bones. A bone with a limited blood supply may be more at risk of developing the disease after an injury. The reduced blood supply might be the result of a previous injury to the blood vessels.

Other bones around the lunate may play a role in the disease, too. The **length of the ulna**, the bone of the forearm on the opposite side of the thumb, may be a factor. When the ulna



is shorter than the radius, the lunate bone absorbs more force when the wrist is used for heavy gripping activities. Over time, this extra force may make it more likely for a person to develop Kienbock's disease. The extra forces



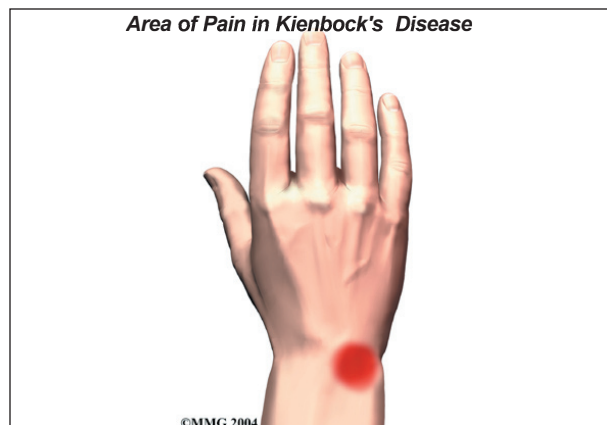make a person more likely to injure the lunate or the blood vessels around it as a result.

Kienbock's disease is also sometimes found in people with other medical conditions that are known to damage small blood vessels of the body. Whatever the cause, the lunate bone develops a condition called **osteonecrosis**. In osteonecrosis, the bone dies, usually because it's not getting enough blood.

## Symptoms

What does Kienbock's disease feel like?

The primary symptoms of Kienbock's disease are pain in the wrist and limited wrist motion. Pain may vary from slight discomfort to constant pain. In the early stages there may be pain only during or after heavy activity using the wrist. The pain usually gets slowly worse over many years. The wrist may swell. The area over the back of the wrist near the lunate bone may feel tender. You may not be able to move your wrist as much as normal or grip objects as well.





Patients often have the condition for months or years before seeking treatment. Typically, the patient will report an injury to the wrist in the past or have a history of repetitive heavy use of the wrist. Kienbock's disease most frequently affects men 20 to 40 years old. It rarely affects both wrists.

## Diagnosis

How do doctors identify the problem?

Your doctor will begin by taking a detailed history of the problem and examining the wrist.

X-rays and possibly a *magnetic resonance imaging* (MRI) scan will be ordered. The X-rays are useful to determine how far the disease has advanced. This helps your doctor plan treatment. The MRI machine uses magnetic waves instead of radiation to take a series of pictures that look like slices of the wrist. The MRI scan is most useful if your doctor is not sure whether the lunate bone has lost its blood supply. The MRI is extremely accurate at showing whether a bone has a blood supply or not. Changes in the lunate bone will usually appear on one of these tests. No other tests are usually required.

## Treatment

What can be done for the condition?

Kienbock's disease usually progresses slowly over many years. To help understand it and recommend what treatment is best, hand surgeons divide the progression of the disease into four stages.

- Stage one: The bone loses its blood supply, and a fracture of the lunate may occur.
- Stage two: The bone hardens (called *sclerosis*) because of the lack of blood supply.
- Stage three: The dead lunate bone collapses. It may break into several pieces and move out of its normal position.

- Stage four: The surfaces of the nearby wrist bones are damaged, resulting in arthritis of the wrist.

Treatment is determined by what stage the disease is in.

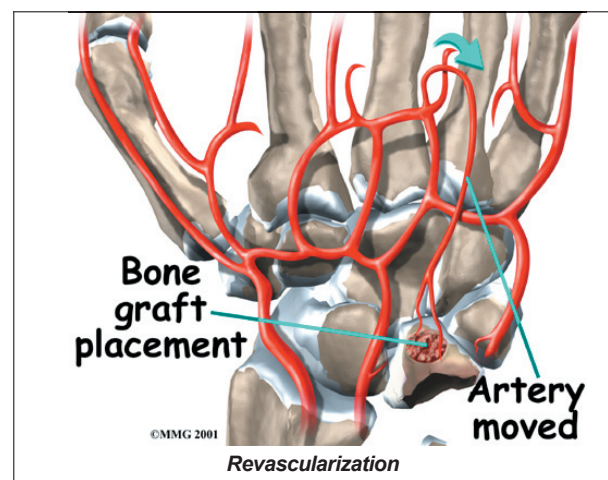
## Nonsurgical Treatment

Stage one Kienbock's disease is usually treated using nonsurgical treatments. Doctors may suggest immobilizing the wrist in a cast for up to three months. It is possible that the blood supply to the lunate will return and the disease will clear up during this time. If the patient has what's known as *transient* (meaning short-lived) osteonecrosis rather than true Kienbock's disease, the condition may also clear up during this time. Transient osteonecrosis sometimes develops briefly after an injury.

## Surgery

### Revascularization

Stage two and stage three Kienbock's disease often require surgery when immobilizing the wrist doesn't help. Attempts to restore the blood flow to the lunate are most likely to be successful at this point. The procedure to restore blood flow is called *revascularization*. During the operation, the surgeon moves a small section of blood vessels (and also possibly bone) from elsewhere on the patient. The segment is attached to the deteriorating lunate bone. This is done to restore blood flow



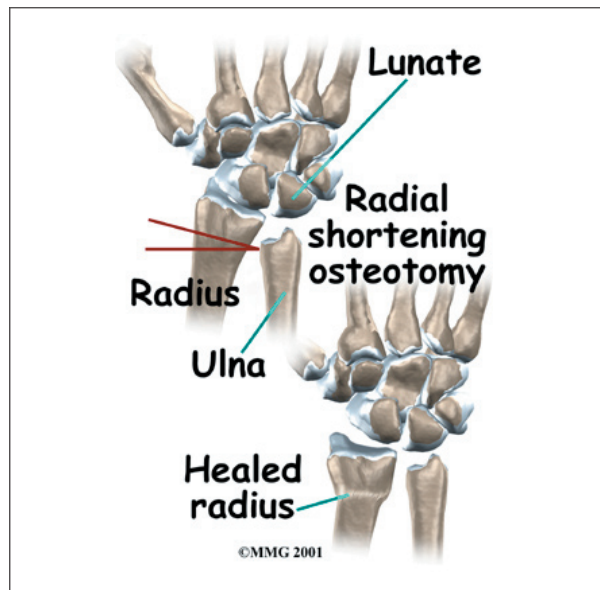
to the lunate and halt its deterioration. This is a newer procedure to treat Kienbock's disease and is not always successful.

### Arthroscopy and Fusion

Using an *arthroscope*, a thin instrument with a TV camera on the end, surgeons are able to operate using a small incision over the lunate. The surgeon cleans the area around the lunate, and then fuses the lunate to the carpal bone next to it. Bringing an extra blood vessel to revascularize the lunate (described above) is not necessarily a part of the treatment.

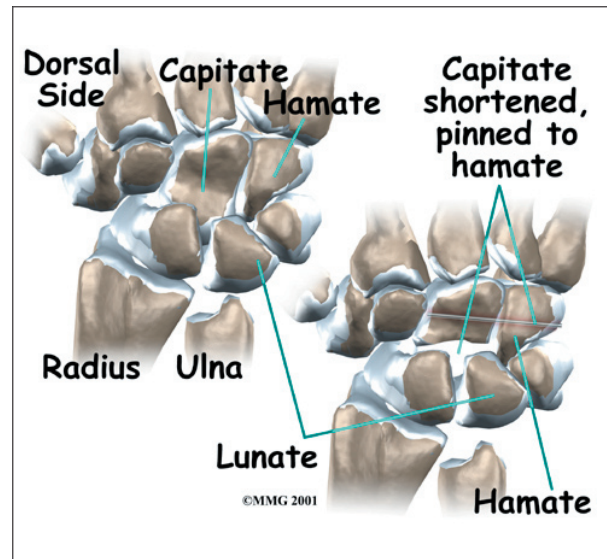
### Lunate Decompression

Other treatment options at this stage include operations designed to take some of the pressure off (*decompress*) the lunate bone. Doing this may allow the bone to heal and revascularize, or it may at least slow the progression of the disease. Operations to do this include a **radial shortening osteotomy**. In this operation, removing a small section of the bone near the wrist shortens the radius bone, allowing the bone to heal together in this shortened position.



### Capitate Shortening

Some surgeons prefer a **capitate shortening** (known as the *Almquist procedure*), which

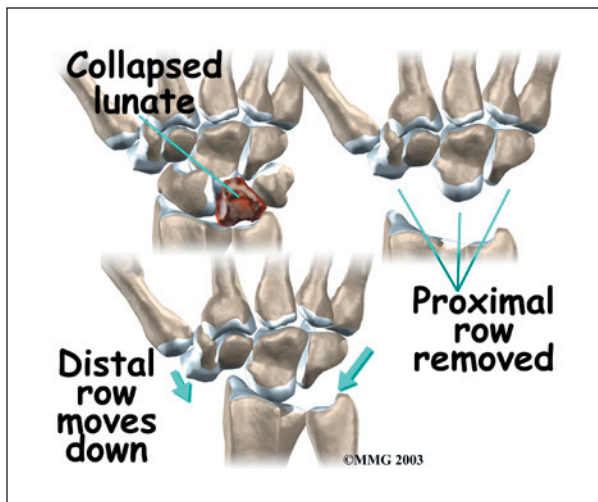


shortens a carpal bone on the other side of the lunate. Lunate decompression and capitate shortening are both helpful for reducing the force on the lunate.

### Carpectomy

In stage four (late-stage) Kienbock's disease, surgeons focus on treating the wrist osteoarthritis that results when the lunate collapses and dies. One surgical option at this stage is *proximal-row carpectomy*. Carpectomy means *excision* (removal) of one or more of the *carpal* bones. The wrist is made up of two rows of carpal bones, four in each row. The lunate is in the *proximal* row (the row closest to the forearm). When the lunate has collapsed, but the wrist joint is not terribly arthritic, the four carpal bones of the proximal row may simply be removed. This allows the *distal* row (the other four bones) to slide down a bit and to begin moving against the forearm bones instead.

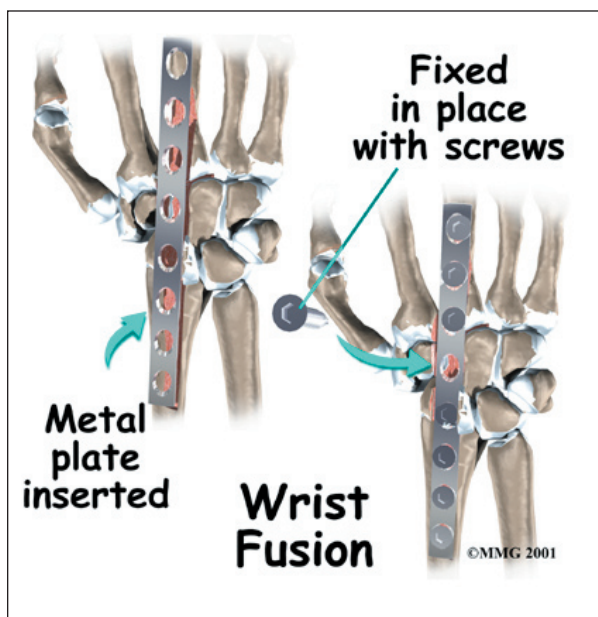
The wrist joint seems to work pretty well after this procedure. The advantage is that you will still have a good deal of wrist motion, unlike wrist fusion (described below). A proximal row carpectomy is a good solution when you need a flexible wrist more than you need a strong one, such as in someone who plays piano for a living.



During this procedure, the surgeon can also take out a section of the nerve that supplies feeling to the wrist joint to reduce wrist pain. This will not affect the feeling in your hand, because it only affects the nerve that goes to the wrist joint itself, below the skin level.

### Wrist Fusion

Finally, your surgeon may also suggest a *wrist fusion* when the entire wrist has become arthritic. (A wrist fusion is sometimes called an *arthrodesis* of the wrist). A fusion is an operation that allows all the bones of the wrist to grow together to form one bone. This makes the wrist stiff. You will not be able to bend the wrist after a fusion. You will be able to turn



the wrist palm up and palm down. A fusion is a good solution when you need a strong wrist more than you need wrist movement, such as someone who does manual labor.

### Rehabilitation

What should I expect from treatment?

#### Nonsurgical Rehabilitation

If the bone is in good alignment, you may be placed in a cast for up to 12 weeks. This amount of time is needed to allow the blood supply to return to the bone. When your doctor is certain the bones have healed, your cast will be removed. Your wrist will probably be stiff and weak from being in the cast. You may need physical or occupational therapy for four to six weeks to help improve wrist range of motion and strength.

#### After Surgery

You'll be placed in a splint for about 12 weeks after surgery. Your surgeon will X-ray the wrist several times after surgery to make sure that the bones are healing properly. Once your wrist has begun to heal, you can safely begin a rehabilitation program.

After surgery, you may need physical or occupational therapy sessions for eight to 12 weeks. The first few treatments will focus on controlling the pain and swelling. You will work into doing exercises to help strengthen and stabilize the muscles around the wrist joint. Other exercises are used to improve fine motor control and dexterity of your hand. You'll be given tips on ways to do your activities while avoiding extra strain on the wrist joint.

## Notes