

## *A Patient's Guide to* **Mucous Cysts of the Fingers**



©MMG 2003



**Centre for Orthopaedics**  
**Suite 10-33/34/35 Mount Elizabeth Novena Specialist**  
**Centre**  
**38 Irrawaddy Road**  
**Singapore, 329563**



## Centre for Orthopaedics

Please take the time to explore our web office. Discover all we have to offer. We hope you will find the time spent on our website rewarding and informative. Here at the Centre for Orthopaedics, we are dedicated to providing ways for those we serve to access the information needed to make informed decisions about healthcare in orthopaedic and sports medicine.

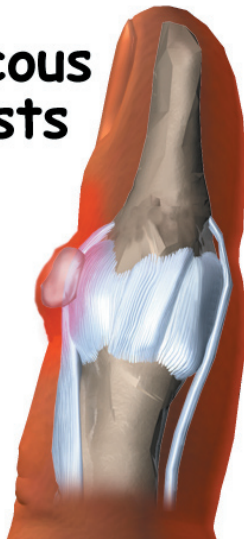We encourage you to explore our site and learn more about our practice, staff, facilities and treatment options. Check out the Patient Resources section of our site. You will find educational materials to help you understand orthopaedic problems and what options for treatment are available in our clinic.

The Staff of the Centre for Orthopaedics.



Centre for Orthopaedics  
Suite 10-33/34/35 Mount Elizabeth Novena Specialist Centre  
38 Irrawaddy Road  
Singapore, 329563  
Phone: (65) 6684 5828 Fax: (65) 6684 5829  
sharon@cfo.com.sg  
<http://www.cfo.com.sg>

## Mucous Cysts



©MMG 2003

### Introduction

*Mucous cysts* are small, fluid-filled sacs that form on the fingers. They are associated with *osteoarthritis* (OA) and usually develop in patients 50 to 70 years old. These cysts appear between the last joint of the finger and the bottom of the fingernail. Unless a mucous cyst is painful or in danger of rupturing, it can be left alone without causing harm to the patient. But even surgically removing a mucous cyst may not alleviate pain if the underlying cause of the pain is OA.

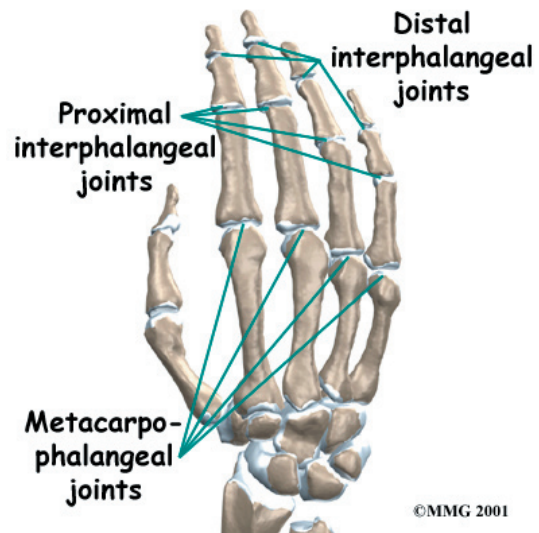
**This guide will help you understand**

- what part of the finger is involved
- how doctors diagnose the condition
- what can be done to treat a mucous cyst

### Anatomy

What part of the finger is involved?

The bones of the fingers are called the *phalanges*. Each finger has three phalanges, separated by two *interphalangeal joints* (IP joints). The one closest to the knuckle is called the *proximal IP joint* (PIP joint). The joint near the end of the finger is called the *distal IP joint* (DIP joint).

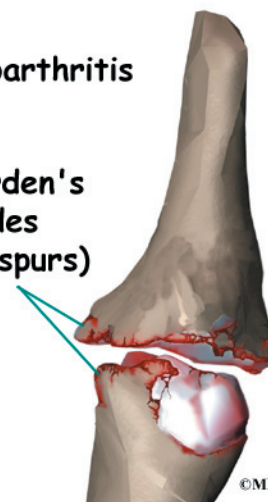


©MMG 2001

*Ligaments* are tough bands of tissue that connect bones. Several ligaments hold each finger joint together. These ligaments join to form the *joint capsule* of the finger joint. The joint capsule is a watertight sac around the joint. The joint surfaces are covered with a material called *articular cartilage*. This material is slick and spongy, and it allows one side of a joint to slide against the other joint surface easily. When this material wears out, the joint develops OA.

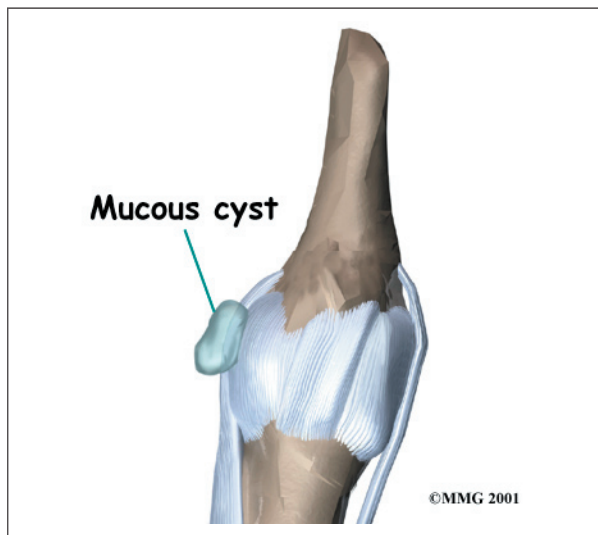
### Osteoarthritis

Heberden's nodes  
(bone spurs)



©MMG 2001

A **mucous cyst** is a type of *ganglion*, a small, harmless sac filled with a clear, sticky fluid. The fluid is a mix of chemicals normally found



in the body. A mucous cyst is a ganglion of the DIP joint. The cyst is attached to the joint by a stalk of tissue. Typically only one cyst appears, though an *occult* (concealed) cyst may also be found closer to the joint.

## Causes

Why do I have this problem?

Mucous cysts are typically found in patients with OA. Doctors do not know why mucous cysts develop.

Doctors also don't understand exactly how these cysts form. One theory suggests that mucous cysts are formed when connective tissue *degenerates* (wears away). Collagen is a protein found in connective tissue. The leftover collagen is thought to collect in pools, and the pools form cysts. Fluid seems to move from the joint into the cyst, but not the other way.

## Symptoms

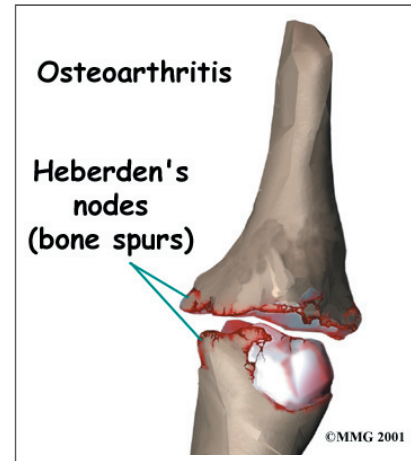
What does a mucous cyst feel like?

A mucous cyst is typically visible just under the skin on the finger. It may be painful. You may notice a groove in the fingernail just above the cyst. The groove is a result of pressure from the cyst on the nailbed. The skin over the cyst may have thinned.

## Diagnosis

How do doctors diagnose the condition?

Your doctor will ask for a history of the problem and examine your fingers. Your doctor may also order an X-ray. An X-ray of the DIP joint may show degeneration related to OA, including bone spurs, joint space narrowing, and hardening of the *subchondral bone*, the layer of bone just below the articular cartilage in the joint. A patient may also have **Heberden's nodes**. These are simply the bumps formed by bone spurs arising from the finger joint due to the OA.



## Treatment

What can be done for the condition?

Treatment for mucous cysts may be either nonsurgical or surgical. The relative risks and benefits of any mucous cyst treatment should be considered carefully.

### Nonsurgical Treatment

Observation is often sufficient treatment for mucous cysts. Mucous cysts are not typically harmful and usually do not grow worse without treatment.

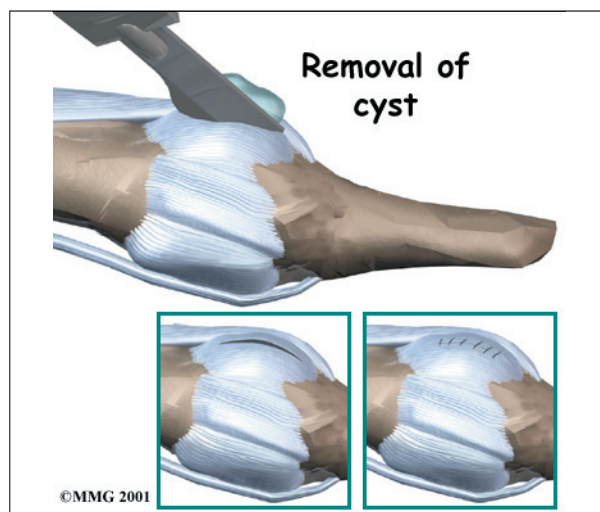
However, sometimes a mucous cyst will rupture. When this occurs, it creates a path directly into the joint where bacteria could enter and cause a serious infection inside the joint. When this happens, antibiotics are applied directly to the site and the finger is wrapped in a dressing. Oral antibiotics are also prescribed. If the joint develops an infection

despite these steps, surgery is required. During surgery, the area, including the DIP joint, is carefully cleaned, and a dressing is applied.

### Surgery

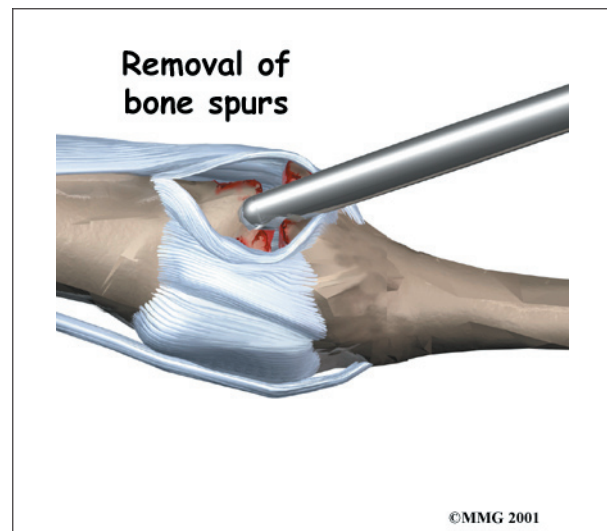
Surgery is recommended if you feel significant pain or if the cyst and skin appear ready to rupture.

Needle puncture is one option. In this procedure, the cyst is punctured and aspirated. (*Aspiration* means drawing the fluid out with suction.) However, this procedure has less than a 50 percent success rate.



Another option involves **excision** (removal) of the cyst and its connection to the DIP joint. Patients should be aware that removing a mucous cyst may not eliminate pain if the pain is from the underlying OA.

In this procedure, the cyst, stalk, and any **bone spurs** on the DIP joint are removed. If the skin on the finger is too closely attached to the cyst, a bit of the skin may need to be removed from the finger. If that's the case, a small skin graft is added to the spot. Surgery can usually be performed using *regional anesthesia*, meaning only the arm or finger is numbed with lidocaine.



Complications may occur with both procedures. A slight risk of infection exists with both. Even after an excision surgery, a mucous cyst may reappear, though this is rare.

### Rehabilitation

What should I expect with treatment?

#### Nonsurgical Rehabilitation

Your doctor may simply have you observe for any changes in the cyst. During this period of observation, let your doctor know of any significant increases or decreases in the size of the cyst.

#### After Surgery

If you have surgery to remove a mucous cyst and a skin graft is used, you will wear a cast or splint for two weeks. Otherwise, the fingers can be moved sooner. You will be shown specific exercises to help you regain full motion in the finger. Exercises should be continued until you can move the finger normally without pain.

## Notes