

A Patient's Guide to **Adult-Acquired Flatfoot Deformity**



Mackie Orthopaedics
Lower Level 2, Calvary Medical Centre
49 Augusta Road
Lenah Valley, Tas 7008
Phone: 61362281490 Fax: 61362281449



Mackie Orthopaedics



The information provided in these pages is licensed from an American surgical multimedia information provider. It represents general information on a variety of orthopaedic topics. The information may not always be entirely relevant to Australian assessments and management.

Dr Mackie does provide additional information to the majority of patients presenting for assessment and treatment of orthopaedic conditions. Questions arising from the content of these information pages may require a review consultation with Dr Mackie.

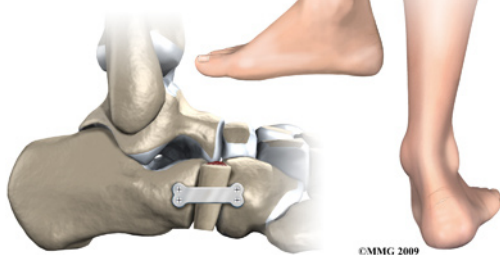
Dr Mackie has provided adult and paediatric orthopaedic care in Hobart since 2005. Services are provided to the Royal Hobart Hospital and all private hospitals. Most paediatric orthopaedic care is provided at the Royal Hobart Hospital due to the additional supports required.

Please contact Dr Mackie's office if you wish to arrange consultation or further information.



Mackie Orthopaedics
Lower Level 2, Calvary Medical Centre
49 Augusta Road
Lenah Valley, Tas 7008
Phone: 61362281490 Fax: 61362281449
clinic@mackie.net.au
<http://www.mackie.net.au>

Adult Acquired Flatfoot



Introduction

Adult-acquired flatfoot deformity (AAFD) is a painful condition resulting from the collapse of the *longitudinal* (lengthwise) arch of the foot. As the name suggests, this condition is not present at birth or during childhood. It occurs after the skeleton is fully matured.

In the past it was referred to a *posterior tibial tendon dysfunction* (or insufficiency). But the name was changed because the condition really describes a wide range of flatfoot deformities. AAFD is most often seen in women between the ages of 40 and 60.

This guide will help you understand

- how the problem develops
- how doctors diagnose this condition
- what treatment options are available

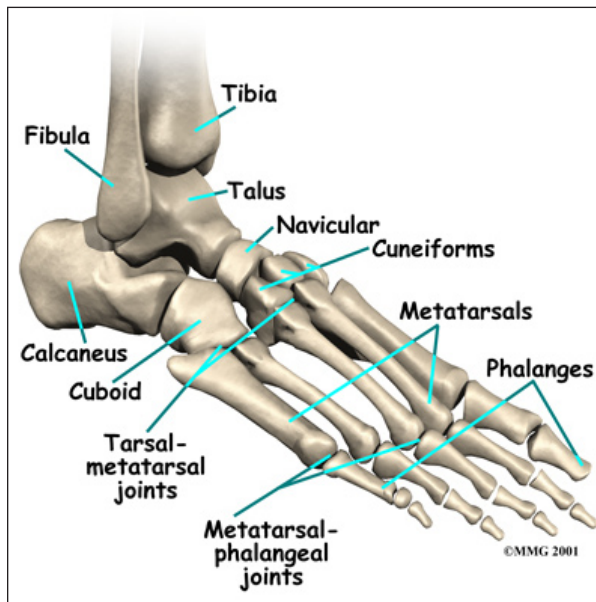
Anatomy

What parts of the foot are involved?

The skeleton of the foot begins with the talus, or ankle bone, that forms part of the ankle joint. The two bones of the lower leg, the large *tibia* and the smaller *fibula*, come together at the ankle joint to form a very stable structure.

The two bones that make up the back part of the foot (sometimes referred to as the hindfoot) are the *talus* and the *calcaneus*, or heel bone. The talus is connected to the calcaneus at the *subtalar joint*. The ankle joint allows the

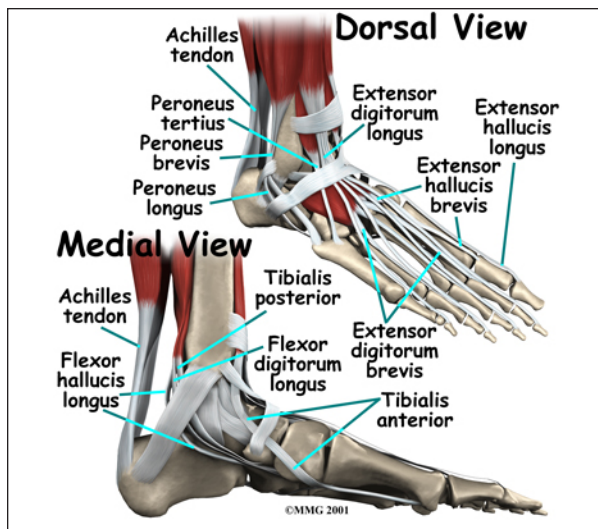
foot to bend up and down. The subtalar joint allows the foot to rock from side to side.



Just down the foot from the ankle is a set of five bones called *tarsal bones* that work together as a group. These bones are unique in the way they fit together. There are multiple joints between the tarsal bones. When the foot is twisted in one direction by the muscles of the foot and leg, these bones lock together and form a very rigid structure. When they are twisted in the opposite direction, they become unlocked and allow the foot to conform to whatever surface the foot is contacting.

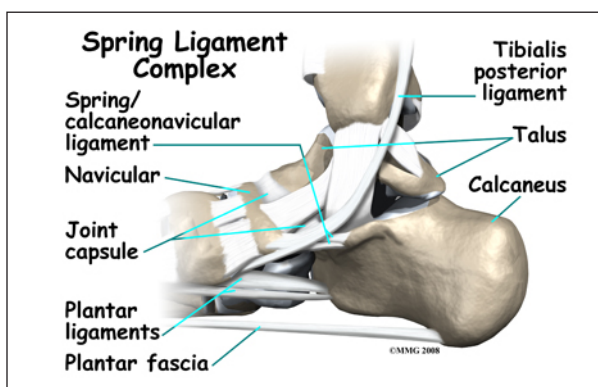
The tarsal bones are connected to the five long bones of the foot called the *metatarsals*. The two groups of bones are fairly rigidly connected, without much movement at the joints.

The large Achilles' tendon is the most important tendon for walking, running, and jumping. It attaches the calf muscles to the heel bone to allow us to rise up on our toes. The posterior tibial tendon attaches one of the smaller muscles of the calf to the underside of the foot. This tendon helps support the arch and allows us to turn the foot inward. Failure of the posterior tibial tendon is a major problem in many cases of adult-acquired flatfoot deformity (AAFD).



The toes have tendons attached that bend the toes down (on the bottom of the toes) and straighten the toes (on the top of the toes). The *anterior tibial tendon* (tibialis anterior) allows us to raise the foot. Two tendons run behind the outer bump of the ankle (called the *lateral malleolus*) and help turn the foot outward.

Many small ligaments hold the bones of the foot together. Most of these ligaments form part of the *joint capsule* around each of the joints of the foot. A joint capsule is a water-tight sac that forms around all joints. It is made up of the ligaments around the joint and the soft tissues between the ligaments that fill in the gaps and form the sac.



The spring ligament complex is often involved in adult-acquired flatfoot. This group of ligaments supports the talonavicular joint. The spring ligament complex works with the posterior tibial tendon and the plantar fascia to

support and stabilize the longitudinal arch of the foot. Failure of the ligaments that support this arch can contribute to flatfoot deformity. Injury, laxity (looseness), or other dysfunction of the ligament and tendon structures can result in deformity of the foot and/or ankle resulting in AAJD.

Causes

What causes adult-acquired flatfoot deformity?

There are multiple factors contributing to the development of this problem. Damage to the nerves, ligaments, and/or tendons of the foot can cause *subluxation* (partial dislocation) of the subtalar or talonavicular joints. Bone fracture is a possible cause. The resulting joint deformity from any of these problems can lead to adult-acquired flatfoot deformity.

Dysfunction of the posterior tibial tendon has always been linked with adult-acquired flatfoot deformity (AAJD). The loss of active and passive pull of the tendon alters the normal biomechanics of the foot and ankle. The reasons for this can be many and varied as well. Diabetes, high blood pressure, and prolonged use of steroids are some of the more common causes of adult-acquired flatfoot deformity (AAJD) brought on by impairment of the posterior tibialis tendon. Overstretching or rupture of the tendon results in tendon and muscle imbalance in the foot leading to adult-acquired flatfoot deformity (AAJD).

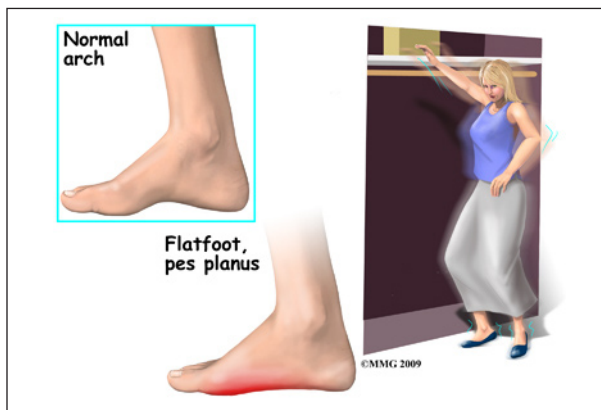
Rheumatoid arthritis is one of the more common causes. About half of all adults with this type of arthritis will develop adult flatfoot deformity over time. In such cases, the condition is gradual and progressive.

Obesity has been linked with this condition. Loss of blood supply for any reason in the area of the posterior tibialis tendon is another factor. Other possible causes include bone fracture or dislocation, a torn or stretched tendon, or a neurologic condition causing weakness.

Symptoms

What does the condition feel like?

At first you may notice pain and swelling along the medial (big toe) side of the foot. This is where the posterior tibialis tendon travels from the back of the leg under the medial ankle bone to the foot. As the condition gets worse, tendon failure occurs and the pain gets worse. Some patients experience pain along the *lateral* (outside) edge of the foot, too.



You may find that your feet hurt at the end of the day or after long periods of standing. Some people with this condition have trouble rising up on their toes. They may be unable to participate fully in sports or other recreational activities.

Diagnosis

How do doctors diagnose the condition?

The history and physical examination are probably the most important tools the physician uses to diagnose this problem. The wear pattern on your shoes can offer some helpful clues. Muscle testing helps identify any areas of weakness or muscle impairment. This should be done in both the weight bearing and nonweight bearing positions.

A very effective test is the single heel raise. You will be asked to stand on one foot and rise up on your toes. You should be able to lift your heel off the ground easily while keeping

the calcaneus (heel bone) in the middle with slight inversion (turned inward).

X-rays are often used to study the position, shape, and alignment of the bones in the feet and ankles. Magnetic resonance (MR) imaging is the imaging modality of choice for evaluating the posterior tibial tendon and spring ligament complex.

There are four stages of adult-acquired flatfoot deformity (AAFD). The severity of the deformity determines your stage. For example:

- **Stage I** means there is a flatfoot position but without deformity. Pain and swelling from tendinitis is common in this stage.
- **Stage II** there is a change in the foot alignment. This means a deformity is starting to develop. The physician can still move the bones back into place manually (passively).
- **Stage III** adult-acquired flatfoot deformity (AAFD) tells us there is a fixed deformity. This means the ankle is stiff or rigid and doesn't move beyond a neutral (midline) position.
- **Stage IV** is characterized by deformity in the foot and the ankle. The deformity may be flexible or fixed. The joints often show signs of degenerative joint disease (arthritis).

Treatment

What treatment options are available?

Nonsurgical Treatment

Conservative (nonoperative) care is advised at first. A simple modification to your shoe may be all that's needed. Sometimes purchasing shoes with a good arch support is sufficient. For other patients, an off-the-shelf (*prefabricated*) shoe insert works well.

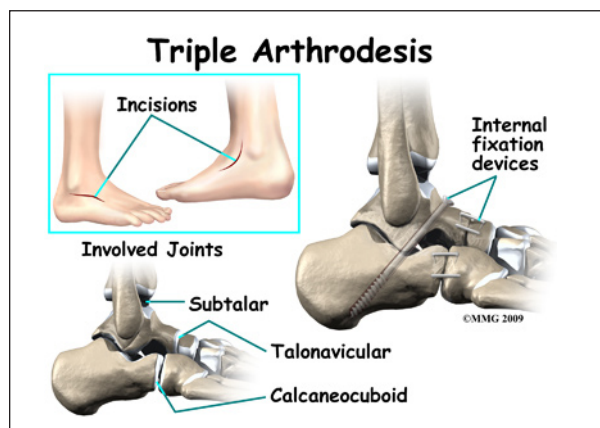
The orthotic is designed specifically to position your foot in good alignment. Like the shoe insert, the orthotic fits inside the shoe. These work well for mild deformity or symptoms.

Over-the-counter pain relievers or anti-inflammatory drugs such as ibuprofen may be helpful. If symptoms are very severe, a removable boot or cast may be used to rest, support, and stabilize the foot and ankle while still allowing function. Patients with longer duration of symptoms or greater deformity may need a customized brace. The brace provides support and limits ankle motion. After several months, the brace is replaced with a foot orthotic.

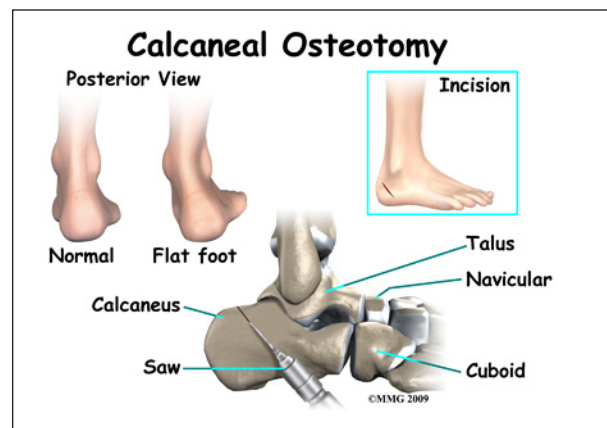
A physical therapy program of exercise to stretch and strengthen the foot and leg muscles is important. The therapist will also show you how to improve motor control and *proprioception* (joint sense of position). These added features help prevent and reduce injuries.

Surgery

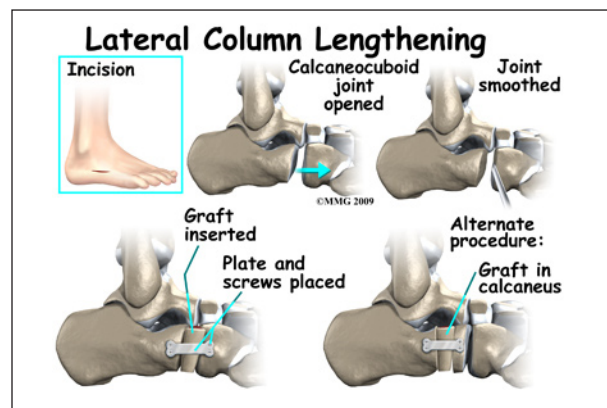
When conservative care fails to control symptoms and/or deformity, then surgery may be needed. The goal of surgical treatment is to obtain good alignment while keeping the foot and ankle as flexible as possible.



The most common procedures used with this condition include *arthrodesis* (fusion), *osteotomy* (cutting out a wedge-shaped piece of bone), and *lateral column lengthening*.



Lateral column lengthening involves the use of a bone graft at the calcaneocuboid joint. This procedure helps restore the medial longitudinal arch (arch along the inside of the foot).



A torn tendon or spring ligament will be repaired or reconstructed. Other surgical options include tendon shortening or lengthening. Or the surgeon may move one or more tendons. This procedure is called a tendon transfer. Tendon transfer uses another tendon to help the posterior tibial tendon function more effectively. A tendon transfer is designed to change the force and angle of pull on the bones of the arch.

It's not clear yet from research evidence which surgical procedure works best for this condition. A combination of surgical treatments may be needed. It may depend on your age, type and severity of deformity and symptoms, and your desired level of daily activity.

Rehabilitation

What should I expect following treatment?

Nonsurgical Rehabilitation

Pain relief and improved function are the two main changes patients report with effective treatment. It's not clear yet if these measures prevent or stop the foot deformity from occurring or getting worse. Some short-term studies (one year) show good results with mild to moderate adult-acquired flatfoot deformity (stages I and II deformity) using orthotic support, foot orthotics, and physical therapy.

Any sign of increasing deformity may be an indication that surgery is needed. Careful monitoring over time is needed to assure the best timing for surgery. Waiting too long can mean a less successful surgical result.

After Surgery

Postoperative care may depend on the type of surgery you have. After a tendon transfer and/or osteotomy, you will be in a cast or removable brace for six weeks. In most cases, you won't be allowed to put weight on the foot during this time. This is especially true if you've had a tendon transfer or bone fusion.

A physical therapist will help you progress from nonweight-bearing to full weight-bearing status. You will probably be wearing a removable boot and starting range of motion exercises. Strengthening exercises can begin when the tendon transfer has healed. At this point you may still have some painful symptoms.

Significant improvement occurs gradually over a four-to-six month period of time. During that time, you will progress in your exercise program. The removable boot will be replaced with a foot orthosis and lace-up shoes. For those patients who have a fusion, you can expect some stiffness and loss of motion in the

foot and/or ankle. The amount and location of the stiffness depends on which bones were fused together.

Studies show that long-term results of just reconstructing the posterior tibial tendon have been disappointing. As much as a 50 per cent failure rate has been reported. This is probably because of the complexity of soft tissue interactions needed to maintain structural integrity of the foot. Reconstructing the spring ligament complex or using an osteotomy to lengthen the lateral side of the foot along with a tendon transplant is more likely to restore more normal foot and ankle movement with better results.

Prolonged swelling and discomfort are not uncommon even six to 10 months after the surgery. Standing on your feet for a long time or walking long distances can also cause foot pain or discomfort.

Notes