

A Patient's Guide to **Dupuytren's Contracture**



©MMG 2003



Dr. Ammar Anbari
Orthopedic Partners
82 New Park Ave
North Franklin, CT 06254
Phone: 860-889-7345



Dr. Ammar Anbari



This education section was created to help my patients and referring physicians learn more about common orthopedic and sports injuries.

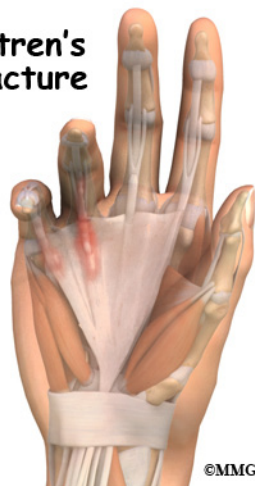-Dr. Anbari

www.CTSportsDoc.com



Dr. Ammar Anbari
Orthopedic Partners
82 New Park Ave
North Franklin, CT 06254
Phone: 860-889-7345
<http://www.CTSportsDoc.com>

Dupuytren's Contracture



Introduction

Dupuytren's contracture is a fairly common disorder of the fingers. It most often affects the ring or little finger, sometimes both, and often in both hands. It occurs most often in middle-aged, white men. This condition is seven times more common in men than women. Although more common in men of Scottish, Scandinavian, Irish, or Eastern European ancestry researchers agree that genes are not a direct cause of this disease, but predisposes them to this condition.

The condition is noted to be secondary to an increase in fibroblast density – a complex biochemical and cellular interaction. The disorder may occur suddenly but more commonly progresses slowly over a period of years. The disease usually doesn't cause symptoms until after the age of 40.

This guide will help you understand

- how Dupuytren's contracture develops
- how the disorder progresses
- what treatment options are available

Anatomy

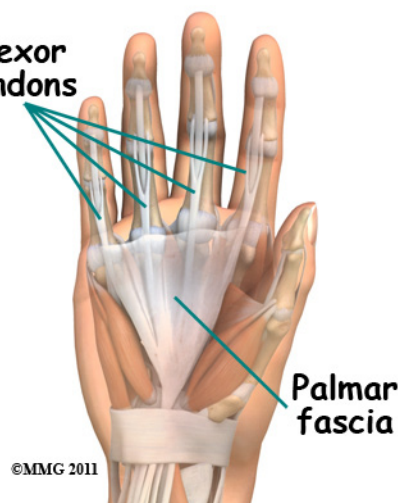
What part of the hand is affected?

The palm side of the hand contains many nerves, tendons, muscles, ligaments, and

bones. This combination allows us to move the hand in many ways. The bones give our hand structure and form joints. Bones are attached to bones by *ligaments*. Muscles allow us to bend and straighten our joints. Muscles are attached to bones by *tendons*. Nerves stimulate the muscles to bend and straighten. Blood vessels carry needed oxygen, nutrients, and fuel to the muscles to allow them to work normally and heal when injured. Tendons and ligaments are connective tissue. Another type of connective tissue, called *fascia*, surrounds and separates the tendons and muscles of the hand.

Lying just under the palm is the **palmar fascia**, a thin sheet of connective tissue shaped somewhat like a triangle. This fascia covers the tendons of the palm of the hand and holds

Flexor tendons

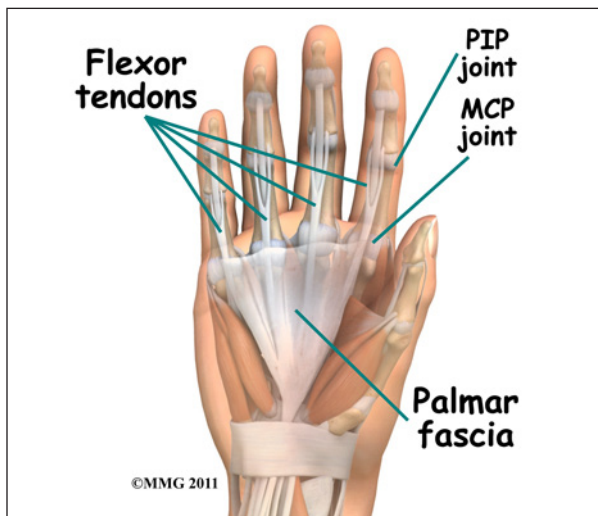


Palmar fascia

them in place. It also prevents the fingers from bending too far backward when pressure is placed against them. The fascia separates into thin bands of tissue at the fingers. These bands continue into the fingers where they wrap around the joints and bones. Dupuytren's contracture transforms the fascia into shortened cords.

The condition commonly first shows up as a thick nodule (knob) or a short cord in the palm of the hand, just below the ring finger. More nodules form, and the tissues thicken and

shorten until the finger cannot be fully straightened. Dupuytren's contracture usually affects only the ring and little finger. The contracture spreads to the joints of the finger, which can become permanently immobilized.



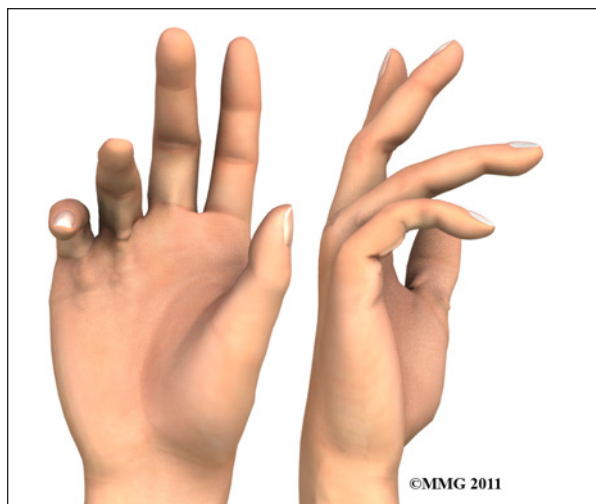The areas affected most often are the *metacarpophalangeal* (MCP) and *proximal interphalangeal* (PIP) joints. The MCP joints are what we usually refer to as the “knuckles.” The PIP joints are the middle joints between the knuckles and the joints at the tips of the fingers.

Flexion contractures usually develop at the metacarpophalangeal (MCP) joints first. As the disease spreads from the palm down to the fingers, the proximal interphalangeal (PIP) joints start to be affected as well.

Causes

Why do I have this problem?

Researchers have studied Dupuytren's contracture and have found this to be a complex interaction of biochemical and cellular processes. The treatment options in the future will rely on pharmacologic interventions rather than surgery alone. This condition is rare in young people but becomes more common with age. When it appears at an early age, it usually progresses rapidly and is often very severe. The condition tends to progress more quickly in men than in women.



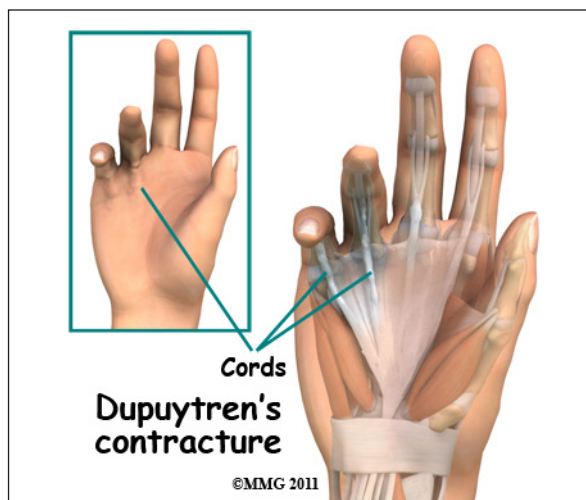
People who smoke have a greater risk of having Dupuytren's contracture. Heavy smokers who abuse alcohol are even more at risk. Recently, scientists have found a connection with the disease among people who have diabetes. It has not been determined whether or not work tasks can put a person at risk or speed the progression of the disease.

Symptoms

What does Dupuytren's contracture feel like?

Normally, we are able to control when we bend our fingers and how much. How much we flex our fingers determines how small an object we can hold and how tightly we can hold it. People lose this control as the disorder develops and the palmar fascia contracts, or tightens. This contracture is like extra scar tissue just under the skin. As the disorder progresses, the bending of the finger becomes more and more severe, which limits the motion of the finger.

Without treatment, the contracture can become so severe that you cannot straighten your finger, and eventually you may not be able to use your hand effectively. Because our fingers are slightly bent when our hand is relaxed, many people put up with the contracture for a long time. Patients with this condition usually seek medical advice for cosmetic reasons or the loss of use of their hand. The condition usually isn't painful, but the nodules can



be sensitive to touch. For this reason many patients are worried that something serious is wrong with their hand.

Diagnosis

How do doctors identify the problem?

Your doctor will ask you the history of your problem, such as how long you have had it, whether you've noticed it getting worse, and whether it has kept you from doing your daily activities. The doctor will then examine your hands and fingers.

Your doctor can tell if you have a Dupuytren's contracture by looking at and feeling the palm of your hand and your fingers. Usually, special tests are unnecessary. Abnormal fascia will feel thick. Cords and small nodules in the fascia may be felt as small knots or thick bands under the skin. These nodules usually form first in the palm of the hand. As the disorder progresses, nodules form along the finger.

These nodules can be felt through the skin, and you may have felt them yourself. Depending on the stage of the disorder, your finger may have started to contract, or bend.

The amount you are able to bend your finger is called *flexion*. The amount you are able to straighten the finger is called *extension*. Both are measured in degrees. Normally, the fingers will straighten out completely. This is consid-

ered zero degrees of flexion (no contracture). As the contracture causes your finger to bend more and more, you will lose the ability to completely straighten out the affected finger. How much of the ability to straighten out your finger you have lost is also measured in degrees.

Measurements taken at later follow-up visits will tell how well treatments are working or how fast the disorder is progressing. The progression of the disorder is unpredictable. Some patients have no problems for years, and then suddenly nodules will begin to grow and their finger will begin to contract.

The *tabletop test* may also be done. The tabletop test will show if you can flatten your palm and fingers on a flat surface. You can follow the progression of the disorder by doing the tabletop test yourself at relatively regular intervals. Put your hand flat on a table and if you can see sunlight between your hand and the table, it's time to start to consider treatment for the condition. Your doctor will tell you what to look for and when you should return for a follow-up visit.

Treatment

What can be done for the condition?

There are two types of treatment for Dupuytren's contracture: nonsurgical and surgical. The best course of treatment is determined by how far the contractures have advanced. Palmar Fascia Removal (palmar fasciectomy) or release of the diseased cords still remains the "gold standard" of care for advanced Dupuytren's contracture.

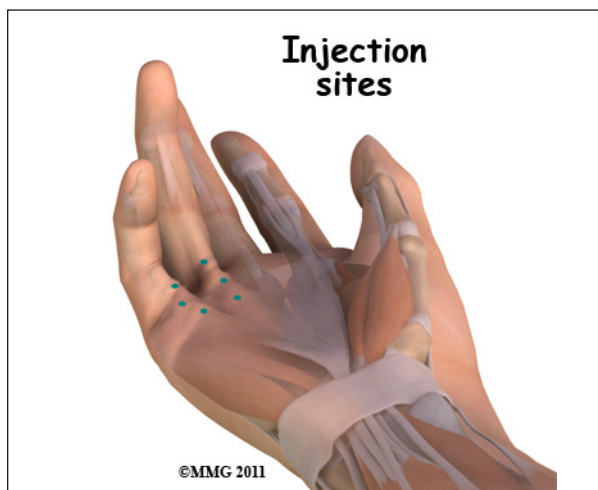Bracing and stretching of the fingers alone has not been proven to help in the long term progression of this condition.

Nonsurgical and surgical treatments are to treat the contracture itself. This does not cure the disease. Dupuytren's disease continues to slowly form the bands although it may be years before the contracture presents itself

again.

Nonsurgical Treatment

The nodules of Dupuytren's contracture are almost always limited to the hand. If you receive regular examinations, you will know when to proceed with the next treatment step. Dupuytren's contracture is a progressive



disease, early treatment, determined by the stage of the disease, is important to release the contracture and to prevent disability in your hand. Treatment is determined based on the severity of the contracture.

Enzymatic Fasciotomy

Ongoing research of this condition has resulted in a less invasive method of treatment called an *enzymatic fasciotomy*, if only the MCP joint is contracted, and there are only one or two cords involved, this procedure may be possible. It may eventually replace surgery. Until then, surgical release of the cords will likely remain the gold standard.

The U.S. Food and Drug Administration (FDA) recently approved a new injectable drug (Xiaflex) for nonsurgical treatment of this problem. By injecting an enzyme directly into the cords formed by the disease, the tissue dissolves and starts to weaken, most often he/she is able to break apart the cord himself/herself.

Generally patients return within 24 hours for recheck. If the cord hasn't broken apart, your physician may have to numb the finger and then stretch the finger to break apart the cord to regain full motion of the finger. That sounds dramatic -- it's not! The treatment is safe and effective. But further study is needed to assess the long-term effects, especially recurrence rates.

There are a few possible (minor) side effects but very few major or long-term complications with this new treatment. During the control trials conducted with patients, most people had a local skin reaction (swelling, redness, skin tears, itching or stinging) where the injection went into the skin. A small number of more serious problems developed in a few patients including skin infection, tendon rupture, finger deformity, complex regional pain syndrome (pain and stiffness), and hives that had to be treated with medication.

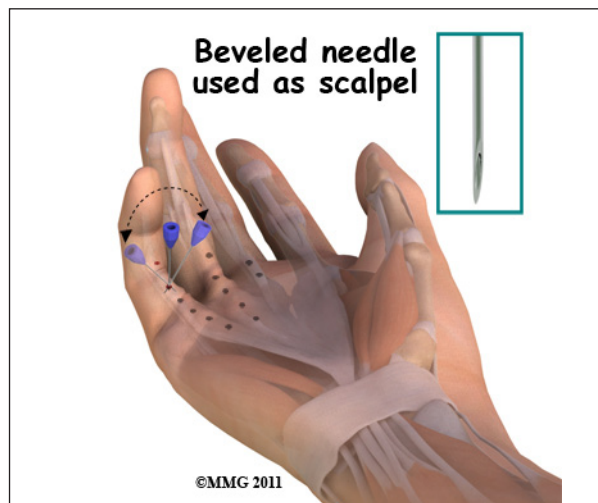
Early studies show a good success rate (77 per cent) in reducing MCP contractures using this injection treatment. Almost all of the patients (92 per cent) were able to straighten the MCP joints with less than a 30-degree flexion contracture. Results were not quite as good for the PIP joints. Less than half (44 per cent) of the patients with PIP contractures had regained full motion of the affected joint. The long-term results and recurrence rates with enzyme fasciotomy are unknown at this time.

Surgery

No hard and fast rule exists as to when surgery is needed. But the sooner a contracture is treated, the better the results of a return to full function. Many patients are instructed to keep an eye on the disease and return for follow-up once their "tabletop test" shows light between their hand and the table.

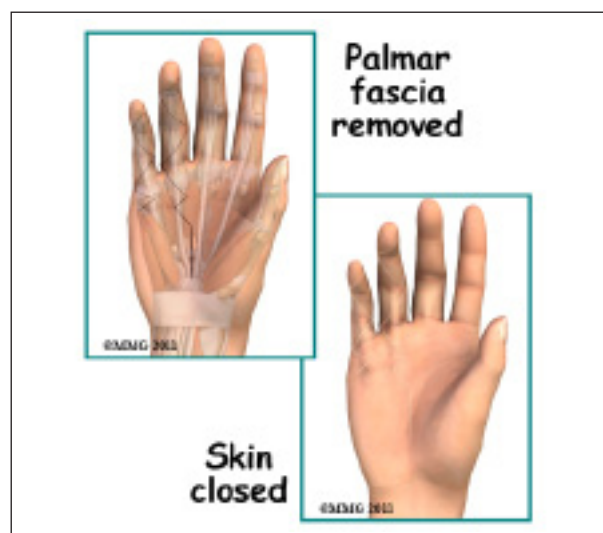Surgery is usually recommended when the MCP joint (at the knuckle) of the finger

reaches 30 degrees of flexion. When patients have severe problems and require surgery at a younger age, the problem often comes back



later in life. When the problem comes back or causes severe contractures, surgeons may decide to fuse the individual finger joints together. In the worst case, amputation of the finger may be needed if the contracture restricts the nerves or blood supply to the finger.

Surgery for the main knuckle of the finger (at the base of the finger) has better long-term results than when the middle finger joint is tight. Tightness is more likely to return after surgery for the middle joint.



The goal of tissue release surgery is to release the fibrous attachments between the palmar fascia and the tissues around it, thereby releasing the contracture. Once released, finger movement should be restored to normal. If the problem is not severe, it may be possible to free the contracture simply by cutting the cord under the skin.

Needle Aponeurotomy

A less invasive procedure called a *needle aponeurotomy* (also referred to as a *percutaneous fasciotomy*) is available when the disease is at an early stage. Under local anesthesia, the surgeon inserts a very thin needle under the skin. The sharp needle cuts a path through the cord, weakening it enough to stretch and extend or rupture it.

The advantage of this procedure is that it can be done on older adults who have other health issues that might make surgery under general anesthesia too risky. The disadvantage is a high recurrence rate and the potential for nerve injury, infection, and *hematoma* (pocket of blood) formation.

This procedure has replaced the “open fasciotomy” in many practices.

Palmar Fascia Removal (partial or limited palmar fasciectomy)

This remains the gold standard of treatment for Dupuytren's contracture. Removal of the diseased palmar fascia causing the contracture but not the entire fascia will usually give a very good result. Final outcomes depends a great deal on the success of doing the post-operative physical or occupational therapy as prescribed. If you decide to have this surgery, you must commit to doing the therapy needed to make your surgery as successful as possible.

Removal of the entire palmar fascia (*radical fasciectomy*) requires extensive removal of involved and non-involved palmar and digital (finger) fascia. This procedure may be required in cases of severe or recurrent Dupuytren's

contracture. This approach has higher complications rates without providing better success rates so it is not done as often anymore.

Complications of a partial palmar fasciectomy this technique can include permanent nerve damage, joint pain and stiffness, hematoma (pocket of blood), infections, and poor wound healing.

Surgery does not always fully restore range-of-motion and function but it usually increases the ability to extend (straighten) the affected fingers. You should also be aware that the problem can come back and/or spread. In other words, surgery is not always “curative.”

Skin Graft

A *skin graft* may be needed if more extensive removal of the palmar fascia is required. This may be the case when the skin surface has contracted so much that the finger cannot relax as it should and the palm cannot be stretched out flat. Surgeons graft skin from the wrist, elbow, or groin. The skin is grafted into the area near the incision to give the finger extra mobility for movement.

Rehabilitation

What should I expect after treatment?

Nonsurgical Rehabilitation

No formal physical therapy is generally needed for enzyme fasciotomy.

After Surgery

After a needle aponeurotomy usually physical therapy is not required. Patients are advised to keep their hand iced and elevated for two days following the procedure. NO strenuous gripping for one week. After one week, return to activities as tolerated. Occasionally a splint is prescribed for night use.

After a partial palmar fasciectomy, your hand will be bandaged with a well-padded dressing and a splint for support after surgery. Palmar wounds from the incisions take about three to

five weeks to heal.

Physical or occupational therapy sessions will be needed after surgery for up to six weeks. Visits will include heat treatments, soft tissue massage, and vigorous stretching. Therapy treatments after surgery can make the difference in a successful result after surgery.

Studies show that patients with more severe disease (especially affecting the proximal interphalangeal (PIP) joints) have a higher risk of disease recurrence. In fact, for all treatment approaches (surgical and nonsurgical), the metacarpophalangeal (MCP) joints are easier to treat with better outcomes and fewer cases of recurrence.

As many as half of all patients who have surgery report return of flexion contractures within five years of surgery. Patients with PIP contractures seem to have the highest recurrence rates.

Notes