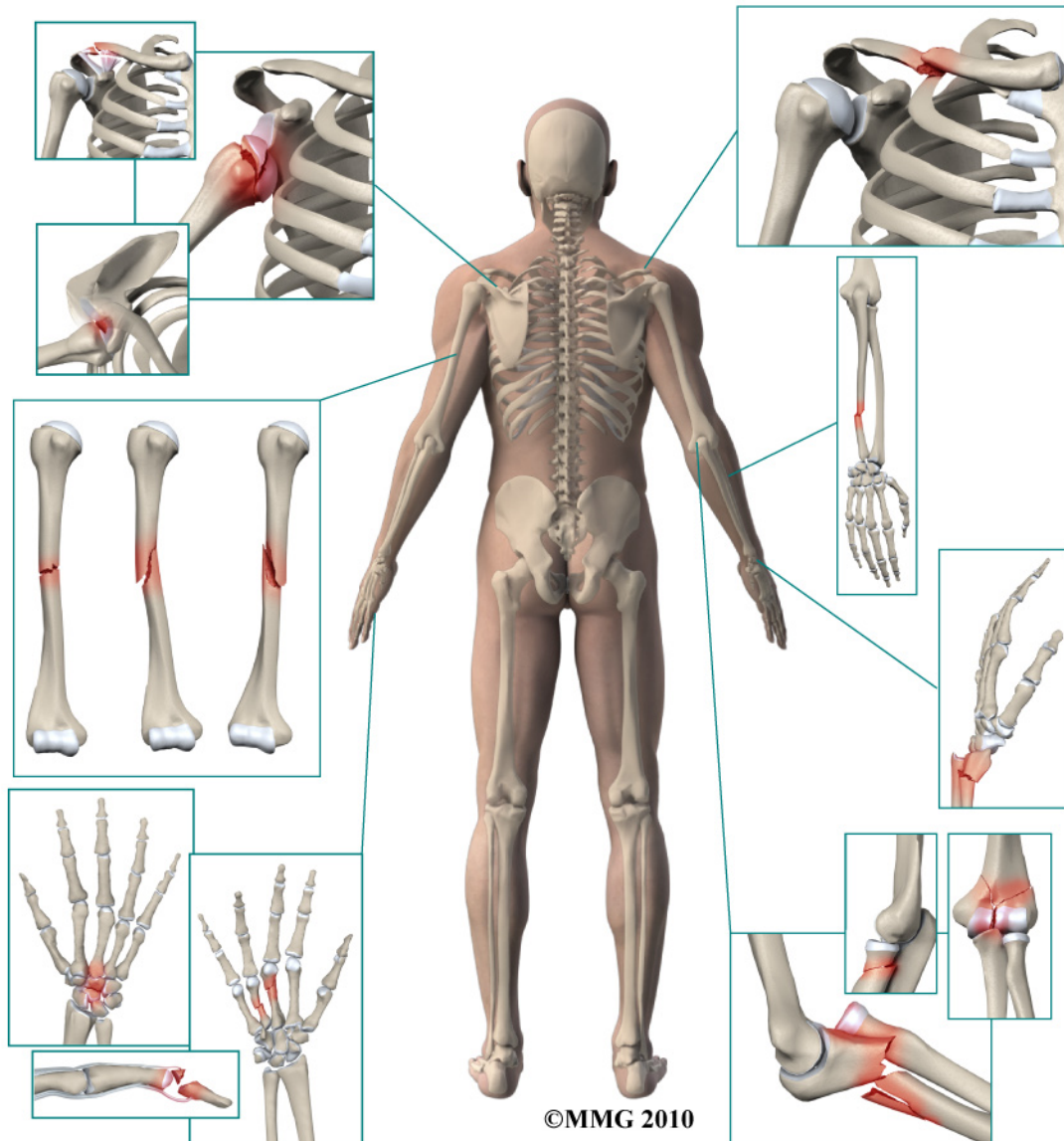


## *A Patient's Guide to* **Adult Clavicle Fractures**



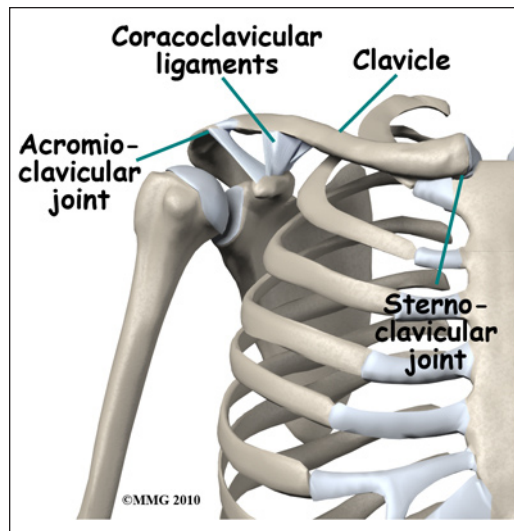
## Medical Multimedia Group L.L.C.



# Adult Clavicle Fractures

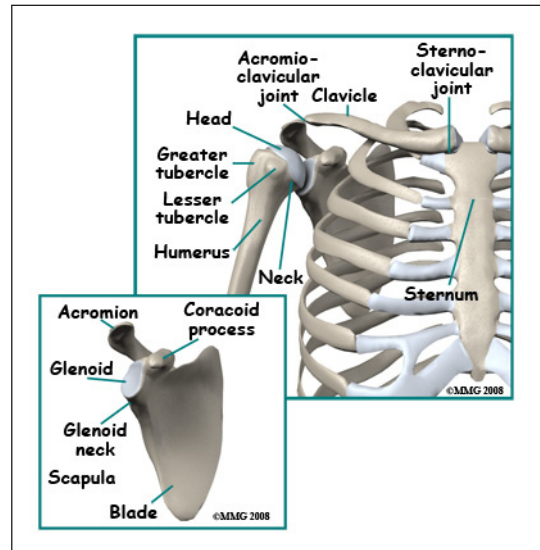
## Anatomy

The *clavicle*, commonly called the "collarbone", forms a strut that connects the rib cage to the *scapula* ("shoulder blade"). The clavicle is important because it stabilizes the shoulder joint and the upper extremity. At its distal end, the clavicle forms a joint with the *acromion* (a part of the scapula). This joint is called the *acromioclavicular* (AC) joint. At proximal end, the clavicle forms a joint with the sternum called the



*sterno-clavicular* (SC) joint. Both of these joints may be injured or dislocated,

but a clavicle fracture combined with an AC or SC joint dislocation is rare. Near the AC joint there are two ligaments that connect the distal clavicle to the *coracoid* (another part of the scapula), the *coracoclavicular* ligaments. These ligaments help stabilize the connection between the clavicle and the scapula.

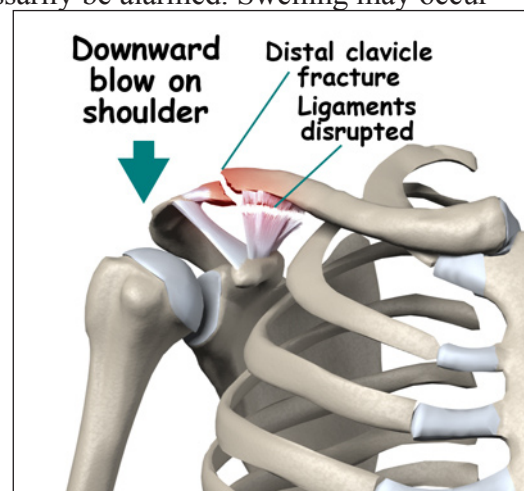


## Signs and Symptoms

A fracture of the clavicle causes pain and swelling in the collarbone area. You will probably not be able to raise the arm. There is usually bleeding into the tissues around the fracture. After several days, there may be intense purple bruising (*ecchymosis*) around the shoulder and down the arm. This is to be expected and you should not necessarily be alarmed. Swelling may occur from the shoulder to the hand. You may feel the bone fragments shift as you move and should not be alarmed if this occurs. You may be able to see the end of one or more fracture fragments pushing outward and stretching (*tenting*) the skin. In some cases the fracture fragment may pierce the skin, turning the fracture into an *open* fracture (also called a *compound* fracture).

## Evaluation

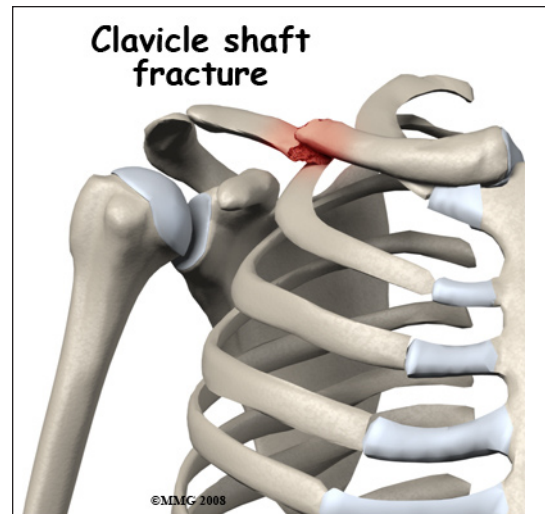
The primary goal of the clinical evaluation of a clavicle fracture is to determine the fracture pattern: what area of the bone has been fractured, how many fragments of bone there are, and how far those fragments are sepa-



rated (or *displaced*). This can be determined by taking several x-rays of the clavicle and shoulder. Your provider will also want to make sure that there has been no damage to the nerves and blood vessels that travel under the clavicle and out to the arm. This can usually be accomplished with a careful physical examination.

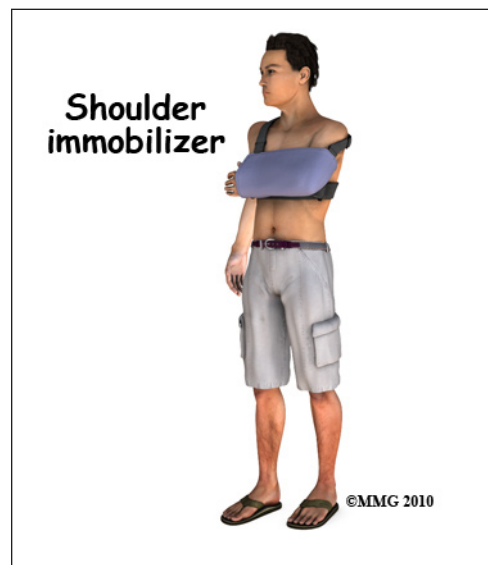
## Treatment

Most clavicle fractures are treated without surgery. The fracture pattern will largely determine whether your surgeon will suggest treating the fracture with or without surgery. Most clavicle fractures occur in the middle third of the bone. These have an excellent chance of healing without surgery. Fractures at the end of the bone near the shoulder are more complicated because of the AC joint and the ligaments that connect the clavicle to the scapula. Fractures in this area may require surgery. If the fracture is open, meaning there is a laceration that connects with the fracture, surgery is required to cleanse the fracture fragments and reduce the risk of infection.

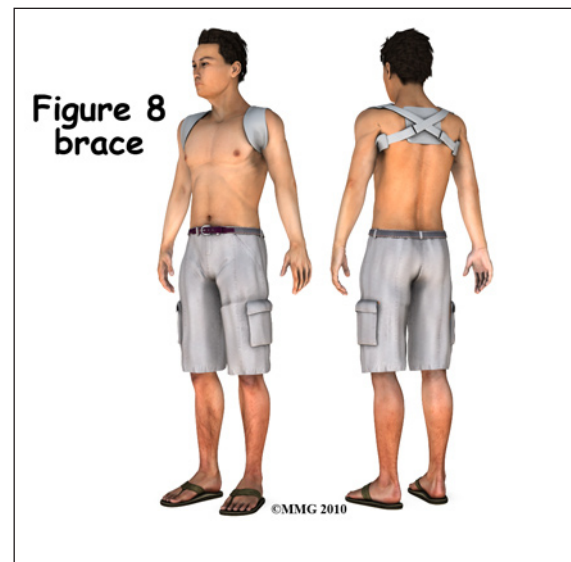


## Non-Surgical

If your provider makes the assessment that the fracture will heal and give you good shoulder function without surgery, nonsurgical treatment will be recommended. Nonsurgical treatment of clavicle fractures generally requires a sling or a special type of sling called a *shoulder immobilizer*. The shoulder immobilizer supports the weight of the arm to keep the shoulder girdle and arm from pulling the fracture fragments further out of alignment. You may feel the bone fragments shift as you move; this usually stops by the third week after the fracture.



A *figure-of-eight clavicle brace* may also be suggested. This brace pulls both shoulders back and helps align the fracture fragments.



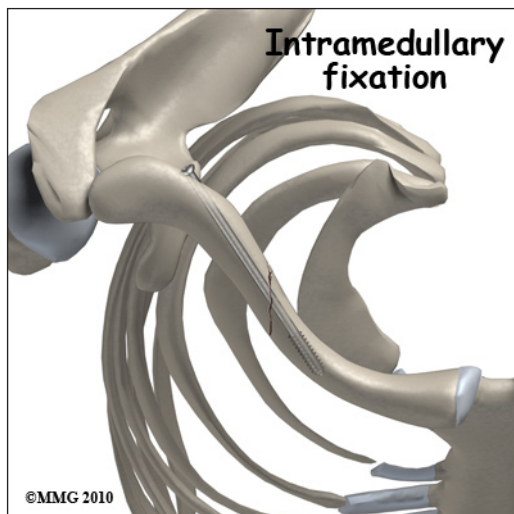
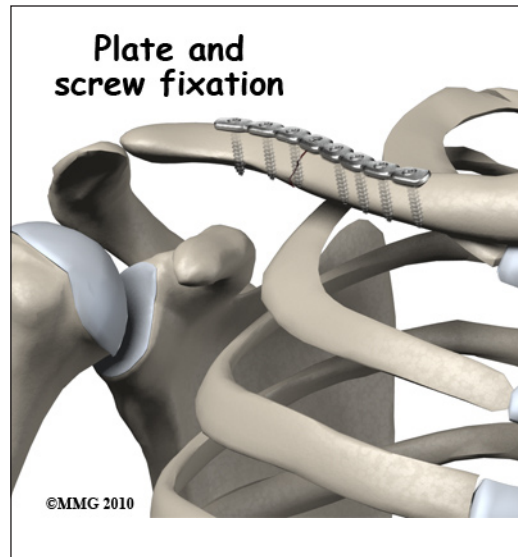


## Surgical

Some clavicle fractures may need surgery. If your provider makes the assessment that the fracture will NOT heal and give you good shoulder function without surgery, surgical treatment will be recommended. Surgical treatment of clavicle fractures is usually performed two ways: a long metal screw inside the bone or a metal plate and screws along the side of the bone.

*Open Reduction and Internal Fixation (ORIF)* of clavicle fractures using a metal plate and screws is common. This type of treatment allows the fracture fragments to be restored as close to their normal position as possible and held there until healing occurs. ORIF requires an incision over the area of the fracture.

The clavicle is very superficial, meaning that the tissue covering the bone is not much more than the skin. In some thin individuals, the plate can be very prominent.



An *intramedullary screw* is also sometimes used to treat clavicle fractures. The intramedullary screw is placed inside the hollow medullary canal of the clavicle. The screw can be inserted into the clavicle through a small incision at the shoulder. The screw is inserted with the aid of a special X-ray machine called a *fluoroscope*. The fluoroscope allows the surgeon to see an X-ray image of the bones on a television monitor and guide the placement of the intramedullary rod by viewing this image.

## Complications

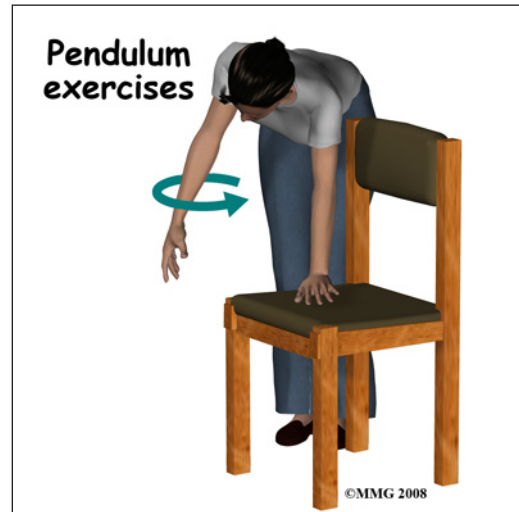
Nearly all fractures can result in damage to nerves and blood vessels, but this is an uncommon complication of clavicle fractures. Large nerves and blood vessels travel beneath the clavicle to the arm and hand. Severe injuries to the shoulder girdle that involve a fracture of the clavicle can injure these nerves and blood vessels.

Infection is possible following any surgical procedure used to treat a fracture, but the risk is very low - less than one in a hundred. The risk is much higher if the fracture is an open fracture. An infection following surgery to repair a fracture may require additional surgery to remove the infected tissue and treatment with antibiotics.

The fracture fragments may fail to heal; this is referred to as a *nonunion*. The fracture fragments may also heal in an unacceptable alignment; this is called *malunion*. Both of these complications may result in pain, loss of strength, and a decreased range of motion of the shoulder. A second operation may be needed to treat the complication.

## Rehabilitation

Most clavicle fractures heal in about three months. During the first two to three weeks, you may feel the fracture fragments shift as you move your arm. This is normal for fractures that have not been treated with surgery. Your rehabilitation exercises will begin as soon as you can tolerate motion with very gentle exercises (*pendulum exercises*) designed to regain motion. Once the fracture has healed enough strengthening exercises will be added to your rehabilitation program. This may occur at six to eight weeks. If surgery has been required, the rehabilitation program will be modified to protect the fixation of the fracture fragments. Your surgeon will communicate with your physical therapist to make sure that your rehabilitation program does not risk causing the fixation to fail. If the surgeon feels that the fixation is very solid, you may be able progress your program quickly; if the fixation is not so solid, the speed at which you progress may need to be slowed until more healing occurs.



The prognosis for clavicle fractures is generally excellent. The shoulder has the largest range of motion of any joint in the body. What this means is that even if the fracture fragments do not heal exactly in their normal position the shoulder joint can easily compensate and provide you with a well functioning shoulder joint.

*NOTE: For further information about fractures visit [www.eOrthopod.com](http://www.eOrthopod.com)*

## Notes